

Structural Integrity and Clinical Outcomes After Arthroscopic Repair of Isolated Subscapularis Tears

By Laurent Lafosse, MD, Bernhard Jost, MD, Youri Reiland, MD,
Stéphane Audebert, MD, Bruno Toussaint, MD, and Reuben Gobezie, MD

Investigation performed at the Department of Orthopaedic Surgery, Alps Surgery Institute, Annecy, France

Background: Isolated tears of the subscapularis occur less commonly than those involving the superior and posterior components of the rotator cuff. The purpose of the present study was to evaluate the structural integrity and clinical outcomes after arthroscopic repair of isolated subscapularis tears.

Methods: A prospective study of seventeen consecutive patients who were managed with an all-arthroscopic repair of the subscapularis tendon was performed. The study group included thirteen men and four women who had an average age of forty-seven years at the time of surgery. The average interval from the onset of symptoms to the time of surgery was twenty-four months. Thirteen tears were traumatic, and four were degenerative. Seven patients had a tear involving the superior third of the tendon, six had a tear involving the superior two-thirds of the tendon, and four had complete separation of the subscapularis from its insertion on the lesser tuberosity. Clinical findings were assessed for all patients preoperatively and postoperatively with use of the Constant and University of California at Los Angeles scoring systems, and all patients had postoperative computed tomographic arthrography studies to evaluate the structural integrity of the repair.

Results: The average duration of follow-up was twenty-nine months. When the preoperative findings were compared with the most recent findings, the average relative Constant score had improved from 58% to 96% ($p < 0.05$), the average University of California at Los Angeles score had improved from 16 to 32 points ($p < 0.05$), the average pain score had improved from 5.9 to 13.5 points ($p < 0.05$), the average forward flexion had improved from 146° to 175° ($p < 0.05$), the average external rotation had improved from 50° to 60.3° ($p < 0.05$), the average internal rotation had improved from the level of the sacrum to L1-L2 ($p < 0.05$), and the average abduction strength had improved from 7.4 to 15.6 points ($p < 0.05$). The structural integrity of the repair was completely intact in fifteen patients and was partially reruptured in two patients on the basis of computed tomographic arthrography. Progression of fatty infiltration of the subscapularis was not observed in any patient. Subjectively, twelve patients were very satisfied with the result, four were satisfied, and one was not satisfied.

Conclusions: Arthroscopic repair of an isolated subscapularis tear can yield marked improvements in shoulder function, can significantly reduce pain, and can result in a durable structural repair.

Level of Evidence: Therapeutic Level IV. See Instructions to Authors for a complete description of levels of evidence.

The treatment of isolated subscapularis tears by means of open repair has been associated with acceptable clinical outcomes in several studies¹⁻⁵. The clinical results of arthroscopic repair of these relatively uncommon tears have

been reported in very few studies with limited follow-up or small patient populations^{6,7}. Although improvements in clinical examination techniques and radiographic imaging have improved our ability to accurately diagnose subscapularis

Disclosure: The authors did not receive any outside funding or grants in support of their research for or preparation of this work. Neither they nor a member of their immediate families received payments or other benefits or a commitment or agreement to provide such benefits from a commercial entity. No commercial entity paid or directed, or agreed to pay or direct, any benefits to any research fund, foundation, division, center, clinical practice, or other charitable or nonprofit organization with which the authors, or a member of their immediate families, are affiliated or associated.

tears, the recognition of partial tears is likely underreported⁸. This problem has led many to a more thorough assessment of the subscapularis during arthroscopy and a greater appreciation for the potential role that this tendon may play as a cause of anterior shoulder pain and biceps instability⁸⁻¹³. The purpose of the present study was to evaluate the functional and anatomic results of arthroscopic subscapularis repair in seventeen patients after a minimum duration of follow-up of two years.

Materials and Methods

Patients

Between May 2000 and July 2002, 342 arthroscopic rotator cuff repairs were performed at our institution. Seventeen patients (4.9%) had an isolated subscapularis tear and were managed with arthroscopic repair of the tendon by the senior surgeon (L.L.); these patients constituted the study group. Fifteen of the seventeen tears in the present study were isolated full-thickness lesions of the subscapularis. During the period of study, a total of 169 patients were identified with subscapularis tears, including those that were associated with other torn rotator cuff tendons. Patients with tears involving any of the other rotator cuff tendons were excluded from the study. The average interval from the onset of symptoms to the time of surgery was twenty-four months (range, three to forty-four months). The indication for surgical repair in this patient population was the identification of a symptomatic subscapularis tear that presented with pain and weakness after a traumatic injury or the failure of nonoperative management in patients with degenerative tendon tears.

The study group included thirteen men and four women who had an average age of forty-seven years (range, twenty-nine to fifty-nine years) at the time of surgery. The dominant side was involved in sixteen of the seventeen patients. Thirteen patients had a traumatic tear that had been caused by combined forced abduction and external rotation (six patients), direct heavy trauma or a blow to the shoulder (four), heavy lifting (two), or severe traction on the arm (one). Six of these thirteen tears were work-related injuries. In the remaining four patients, symptoms developed progressively over a mean of fifteen months without a specific history of trauma.

Clinical and Radiographic Evaluation

Each patient in the present series was evaluated by an independent examiner (Y.R.) preoperatively and postoperatively with use of the Constant and Murley¹⁴ and University of California at Los Angeles (UCLA)¹⁵ scoring systems. Patients were also asked to rate their level of satisfaction with the result as very satisfied, satisfied, or unsatisfied at the time of the most recent postoperative evaluation. Clinically, the diagnosis of a subscapularis tendon tear was made with the lift-off and belly-press tests¹. We modified the belly-press test by pushing against the elbows of the patient (Fig. 1-A). In order to better quantify the strength of the subscapularis, we also modified the lift-off test by asking the patient to push against the hand

of the examiner while the arm of the patient was in maximum internal rotation behind the body (Fig. 1-B). Pain was graded on a scale of 0 to 15 according to the scheme from the Constant scoring system, and strength was assessed on a scale from 0 to 5 according to the internationally accepted classification of neurological assessment. On the modified lift-off test, eleven patients had a positive result (meaning that they were able to perform the maneuver although they had less-than-normal strength), one patient had a normal result, and five patients were unable to perform the test because of either pain or stiffness. On the modified belly-press test, nine of the seventeen patients, including four of the five patients who were unable to perform the lift-off test, had a positive result (indicating weakness).

With regard to the biceps tendon, four patients had tenderness over the bicipital groove or a positive Speed test¹⁶. In addition, two patients had clinical evidence of biceps rupture with the so-called Popeye deformity.

Each patient was evaluated with a standard series of plain radiographs (including an axillary view and true anteroposterior views with the arm in neutral, internal rotation, and external rotation) before and after surgery. The presence of glenohumeral osteoarthritis in each patient was classified according to the criteria of Samilson and Prieto for dislocation arthropathy¹⁷ on the basis of the anteroposterior radiograph made with the arm in neutral rotation. None of the patients in the present series had preoperative evidence of arthritis on plain radiographs. In addition, all seventeen patients had preoperative and postoperative computed tomographic arthrography studies to confirm the diagnosis of a subscapularis tear and to evaluate the structural integrity of the repair after surgery. The computed tomographic arthrography studies also were used to classify the degree of fatty infiltration according to the system of Goutallier et al.¹⁸. As was done in the study by Edwards et al.², we simplified the classification in order to facilitate the analysis of our data by considering stages 0 and 1 together as minimal fatty infiltration and stage 2 as intermediate fatty infiltration. None of our patients exhibited stage-3 or 4 fatty infiltration. Preoperatively, fifteen of the seventeen patients were classified as having stage-0 or 1 fatty infiltration and two were classified as having stage-2 fatty infiltration.

Preoperatively, computed tomographic arthrography was used to further classify each subscapularis tear according to size into three categories by dividing the tendon into thirds. Seven patients had a tear involving the superior third of the tendon, six had a tear involving the superior two-thirds of the tendon, and four had complete separation of the subscapularis from its insertion on the lesser tuberosity. None of the patients in the present series had complete disruption of the subscapularis insertion with an eccentric humeral head resulting in subcoracoid impingement.

Operative Technique and Intraoperative Evaluation of Subscapularis Tears

All patients had regional anesthesia with an interscalene block and general anesthesia. The arthroscopic repair was

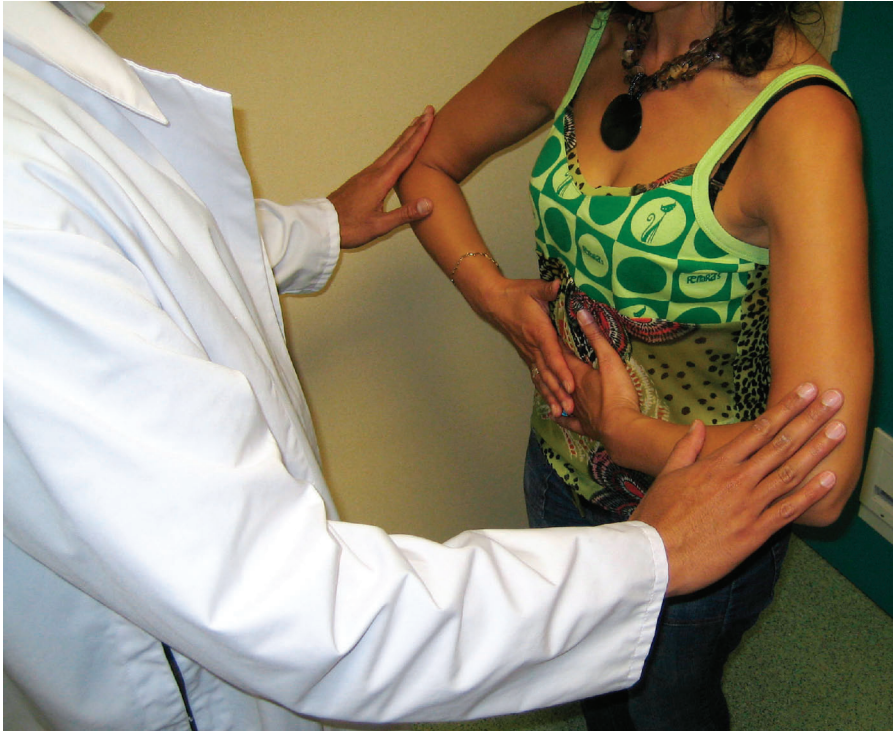

Fig. 1-A

Fig. 1-A The modified belly-press test. The examiner supplies force against the elbows while asking the patient to provide resistance. This maneuver permits grading of subscapularis strength.

Fig. 1-B The modified lift-off test. The examiner supplies force against the hand while asking the patient to provide resistance.

performed with the patient in the beach-chair position with the arm in 60° of forward flexion and with the application of 1.5 to 3 kg of longitudinal traction. We believe that this position has several advantages over the lateral decubitus position when performing arthroscopic repair of the subscapularis. First, we agree with the conclusion of Nove-Josserand et al., who reported that the lateral decubitus position allows for visualization of only the superior 44% of the subscapularis tendon rather than the superior two-thirds that can be visualized with the patient in the beach-chair position⁴. Furthermore, the arthroscopic repair of the subscapularis tendon is often greatly facilitated by manipulation of the arm into varying degrees of rotation and flexion (depending on the tear size and configuration), and this is much easier with the patient in the beach-chair position. Access to the anterior aspect of the shoulder, an important component of our arthroscopic subscapularis repair technique, is also greatly facilitated with the patient in the beach-chair position.

Three to four portals were used, depending on the size of the lesion (Figs. 2-A and 2-B). A 30° arthroscope was introduced into the glenohumeral joint through the posterior “soft-spot” portal. With use of this posterior portal (Portal A), adequate visualization of tears involving the superior two-thirds of the subscapularis tendon without retraction could be achieved (Figs. 2-A and 2-B). However, if visualization was limited with this portal, then we used a lateral portal (Portal C) for the arthroscope within the subacromial space in order to perform the tendon repair (Figs. 2-A and 2-B). Two anterior “working” portals (Portals D and E) were used to perform the débridement, to place the anchors, and to pass the sutures

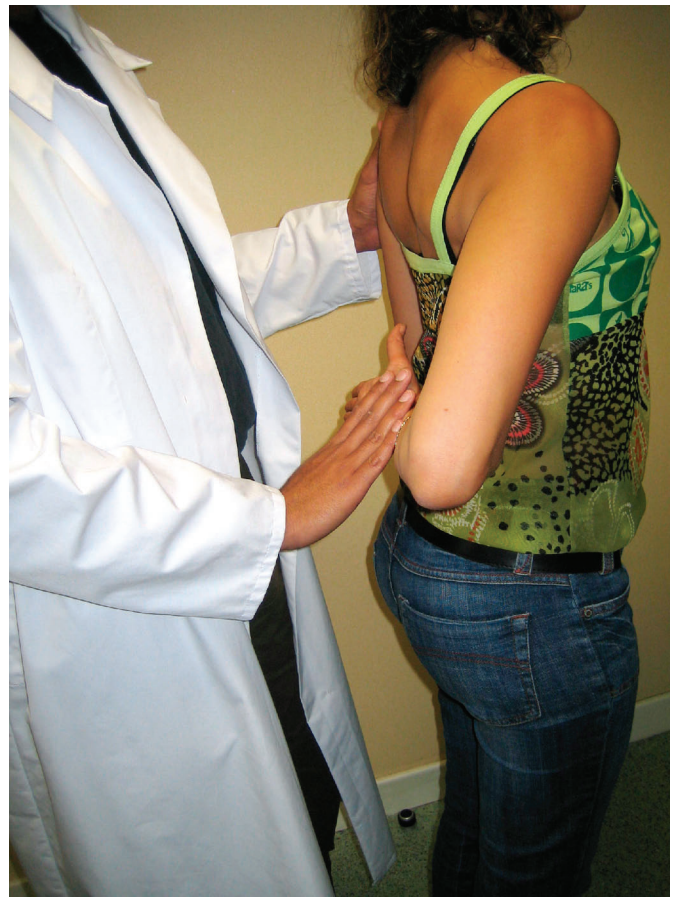


Fig. 1-B

TABLE I Classification of Subscapularis Tears on the Basis of Intraoperative Evaluation and Preoperative Computed Tomography

Type	Lesion	Number of Cases
I	Partial lesion of superior one-third	2
II	Complete lesion of superior one-third	4
III	Complete lesion of superior two-thirds	7
IV	Complete lesion of tendon but head centered and fatty degeneration classified as less than or equal to stage 3	4
V	Complete lesion of tendon but eccentric head with coracoid impingement and fatty degeneration classified as more than or equal to stage 3	0

through the torn tendon. The anterosuperior portal lateral to the coracoid (Portal E) was used to pass the sutures through the torn tendon edge, and an anterolateral portal in the rotator interval (Portal D) was used to release the subscapularis, to débride the subcoracoid space and the lesser tuberosity, and to place the suture anchors. In patients with larger and retracted tears, an anteroinferior portal (Portal F) was used to perform the subscapularis release circumferentially.

In general, ruptures of the subscapularis were readily identified once a careful diagnostic arthroscopy was performed. We employed a new classification scheme in order to further characterize the subscapularis tears arthroscopically and used this classification system to guide our operative approach to the repair of these lesions. In the past, subscapularis tears have been classified as either partial or full thickness and as either isolated or combined with tears of the supraspinatus

tendon^{6,7,19}. We propose a new classification system that achieves two primary aims. First, the classification system accounts for the observation that subscapularis tears occur from the deep to superficial layers—a phenomenon that has been recognized through diagnostic arthroscopy. Second, the classification system guides therapy and differentiates tears that are repairable from those that we believe are not repairable (full-thickness tears with static anterior subluxation of the humeral head on the glenoid, resulting in subcoracoid impingement). According to our classification system, subscapularis tears may be divided into five types (Table I). Type-I tears are localized to the superior third of the subscapularis tendon and are partial tears of the deep fibers at the insertion onto the lesser tuberosity. These tears never display tendon retraction because the superficial fibers of the subscapularis remain intact. Two patients in the present study had this tear pattern. Type-II

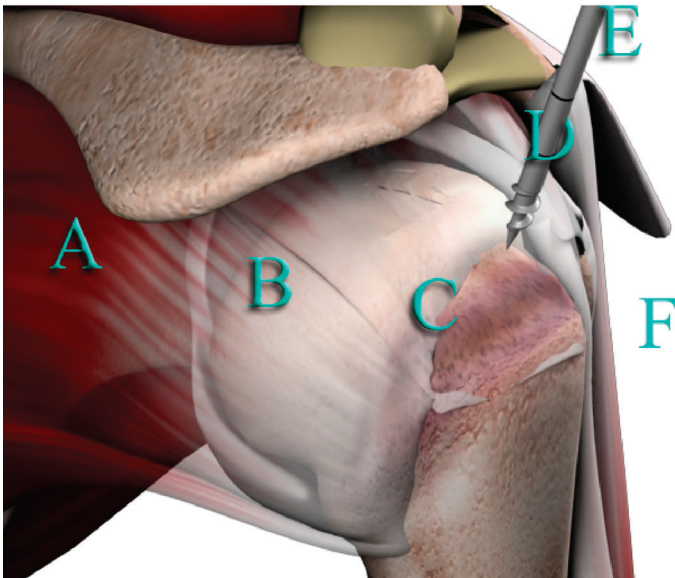


Fig. 2-A

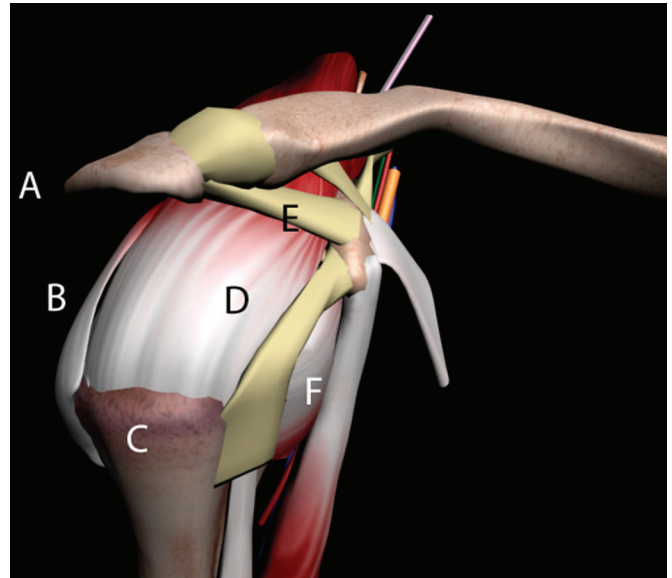


Fig. 2-B

Fig. 2-A Portal placement for arthroscopic subscapularis repair. Portal A is a posterior “soft-spot” portal; Portal B is a posterolateral portal often used for superior and posterosuperior cuff tears; Portal C is a lateral portal sometimes used for the arthroscope; Portal D is an anterolateral portal used for the lesser tuberosity decortication, subscapularis release, and débridement of the subcoracoid space; Portal E is an anterosuperior portal used to pass sutures through the tendon edge; and Portal F is an accessory distal anteroinferior portal used for mobilizing large retracted tears of the subscapularis. **Fig. 2-B** Superior view of shoulder, demonstrating the anterior portals used to perform most of the subscapularis repair. (Permission to reproduce these figures must be obtained from T.A.G. Medical Products, Kibbutz Gatton, Israel.)

tears are complete ruptures that are limited to the superior third of the tendon (including both the superficial and deep fibers). Four patients in the present study had this tear pattern. Type-III tears are complete tears of the superior two-thirds of the subscapularis tendon. The intact inferior one-third of the tendon limits the degree of retraction that may occur with these lesions. Seven patients in the present study had this tear pattern, and all seven of these patients had an intermediate level of tendon retraction between the lesser tuberosity and the glenoid rim with the arm held in neutral rotation. Type-IV tears are complete tears of the entire subscapularis tendon from its insertion, combined with retraction of the tendon edge to the level of the glenoid rim without anterior eccentricity of the humeral head on the glenoid. Four patients in the present study had this tear pattern. Type-V tears are complete tears of the subscapularis with retraction and an eccentric humeral head that is displaced anteriorly on the glenoid because of disruption of the force-couple of the rotator cuff³. None of the patients in the present study had this type of tear because, in our practice, such tears are not treated with arthroscopic repair.

Tears of the superior third of the subscapularis were often covered by a synovial membrane or, less often, by an intact anterior pulley and could be clearly identified after débridement and positioning of the arm in flexion and internal rotation^{20,21}. More extended ruptures with a retracted tendon were frequently combined with detachment of the superior glenohumeral and coracohumeral ligaments from their insertion on the humerus. These ligaments usually were still attached to the superolateral border of the subscapularis tendon, creating the so-called comma sign as described by Burkhart and Tehrany⁶. Although the comma sign can aid in localizing the superior border of the torn subscapularis tendon, none of the patients in the present study had a supraspinatus tear; therefore, débridement of the lesser tuberosity from the subacromial view often was required to correctly identify the tendon edge.

Once the tendon edge was identified, a burr or shaver was used to decorticate the lesser tuberosity in preparation for anchor placement and to optimize the environment for tendon healing. In patients with retracted tears, a circumferential release of the subscapularis tendon was performed with the shaver and an electrothermal device (Vapor; Mitek, Raynham, Massachusetts) in order to mobilize the tendon. It should be noted that the intra-articular release of the subscapularis requires débridement of the middle glenohumeral ligament from the posterior aspect of the subscapularis. Superiorly and anteriorly, the subdeltoid and subcoracoid adhesions were released. In order to improve visualization and to assist in mobilizing the tendon, we also routinely released the origin of the coracohumeral ligament from the coracoid process. A traction suture was often placed through the anterolateral portal in order to facilitate the release of the subscapularis tendon (Fig. 3). The anatomic structure limiting the release of the subscapularis tendon in patients with type-III tears was the axillary nerve. However, in order to mobilize some type-

III and IV subscapularis tears, adhesions between the brachial plexus and the retracted tendon were released and careful dissection was performed in order to avoid damaging the two branches of the subscapular nerve on the anterior surface of the muscle belly. No coracoplasties were performed in this series because patients with an eccentrically positioned humerus associated with a retracted subscapularis tear were not included in the study.

Reinsertion of the tendon was performed with metallic anchors (G4 super anchor; Mitek) loaded with #2 Ethibond sutures. These sutures were passed through the subscapularis tendon with use of a shuttle-relay technique. Reconstruction of the footprint always proceeded from the most inferior aspect of the torn tendon, working proximally. Anchors always were placed along the anterior border of the bicipital groove in order to achieve an anatomic footprint repair. In patients with type-III and IV tears, a mattress suture was used inferiorly and medially and a more simple suture was used laterally over the footprint in an attempt to perform a double-row suture anchor repair. We believe that this repair technique maximizes the contact area for tendon healing and results in a more stable reconstruction.

At the time of surgery, two patients had a rupture of the long head of the biceps tendon. Of the remaining patients, six had a normal biceps tendon, two had mild fraying of the biceps tendon, and seven had a partial tear of the biceps tendon. Nine of the fifteen unruptured biceps tendons with pathologic changes underwent tenodesis with use of suture anchor fixation (G2; Mitek) with a simple suture configuration of #2 Ethibond.

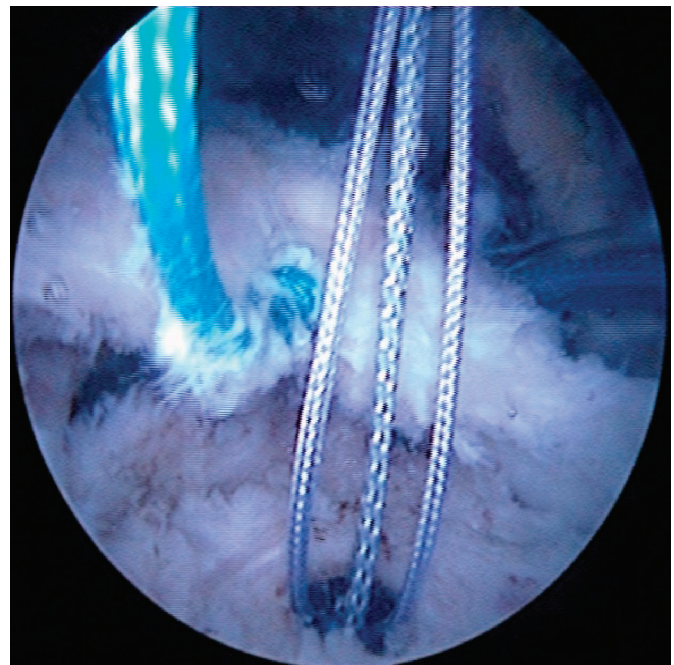


Fig. 3

A traction suture through the subscapularis was sometimes used to facilitate release in patients with larger (type-III and IV) tears

TABLE II Clinical Results

	Preop.*	Postop.*	P Value
Lift-off test (points)			
Pain (maximum, 15 points)	3.3	12.6	<0.001
Strength (maximum, 5 points)	2.3	4.1	<0.001
Belly-press test (points)			
Pain (maximum, 15 points)	5.6	14.1	<0.001
Strength (maximum, 5 points)	2.5	4.4	<0.001
Pain (maximum, 15 points) (points)	5.9	13.5	<0.001
Active forward flexion	145.6°	174.7°	0.005
Active external rotation	50.0°	60.3°	0.03
Internal rotation (maximum, 10 points) (points)	4	7.6	<0.001
Strength (maximum, 25 points) (points)	7.4	15.6	<0.001
Constant score (maximum, 100 points) (points)	52	84.9	<0.001
Relative Constant score	58%	96.4%	<0.001
UCLA score (maximum, 35 points) (points)	16.2	32.1	<0.001

*The values are given as the average.

Evaluation of the Structural Integrity of the Repair

The structural integrity of the subscapularis repair was evaluated by analyzing the reconstruction of the tendon on serial axial and sagittal cuts of the computed tomographic arthrogram. The “water-tightness” of the repair could not be used as a reliable indicator of the integrity of the subscapularis reconstruction. The technique described above for release of the subscapularis tendon for the treatment of full-thickness subscapularis tears (performed for fifteen of the seventeen patients in this study) requires the resection of part or all of the rotator interval in order to achieve a tension-free repair. As such, extravasation of contrast medium is seen routinely during postoperative computed tomographic arthrography (Figs. 4-A and 4-B). The axial and sagittal cuts of the computed tomographic arthrogram were used to determine if there was any evidence of structural failure of the repairs in the present study.

Postoperative Rehabilitation

The shoulder was immobilized in an abduction pillow for six weeks after surgery in order to protect the rotator cuff repair. During this period, only passive motion was allowed, with internal rotation to the abdomen but not behind the back. Passive external rotation to neutral and forward flexion within a range that was not painful for the patient were permitted under the supervision of a physiotherapist during the first six weeks after surgery. Unrestricted active-assisted forward flexion and rotation were allowed after six weeks, and strengthening of the rotator cuff was permitted after three months.

Statistical Analysis

Statistical analysis of preoperative and postoperative paired data were done with the Wilcoxon test. The level of signifi-

cance was set at $p < 0.05$. Multiple-regression analysis was used to evaluate the relative influence of clinical factors (including the age of the patient at the time of surgery, the mechanism of injury to the subscapularis tendon, the duration of symptoms before surgery, and the degree of fatty infiltration) on the clinical outcome.

Results

A total of 169 subscapularis tears (including ten type-I tears, ninety-five type-II tears, and sixty-four type-III and IV tears) were identified at our institution during the study period. Therefore, the prevalence of isolated subscapularis tears in the present series was 10.1% (seventeen of 169).

The sensitivities of the modified lift-off and belly-press tests used in the present study were 91.7% and 70.6%, respectively. The combination of the two examinations identified sixteen of the seventeen patients with a subscapularis tear as four of the five patients who were unable to perform the lift-off test were able to perform the belly-press test. The computed tomographic arthrogram had a sensitivity of 94%, with only one patient having a normal preoperative examination despite having a subscapularis tear that was subsequently identified and repaired arthroscopically.

At the time of the most recent follow-up evaluation, performed at an average of twenty-nine months (range, twenty-four to thirty-nine months) after surgery, twelve patients were very satisfied with the final clinical result, four patients were satisfied, and one was not satisfied.

The preoperative and postoperative Constant scores are shown in Table II. The mean Constant score improved from 52 points preoperatively to 84.9 points postoperatively ($p < 0.001$). The mean age and gender-adjusted Constant score improved from 58% (range, 19% to 80%) preoperatively to

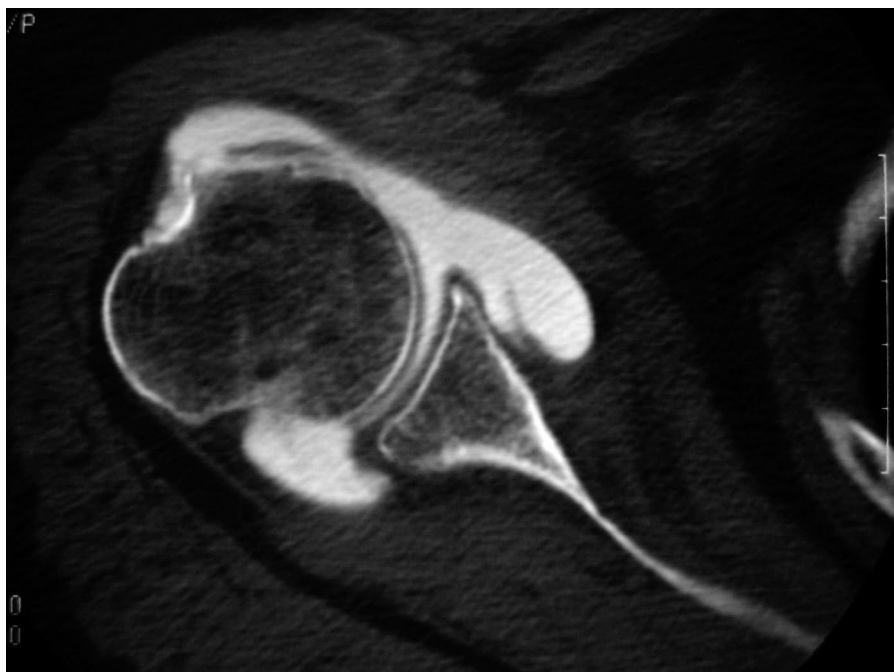


Fig. 4-A
Computed tomographic arthrogram showing a subscapularis tear, with clear detachment of the subscapularis insertion and extravasation of contrast medium.

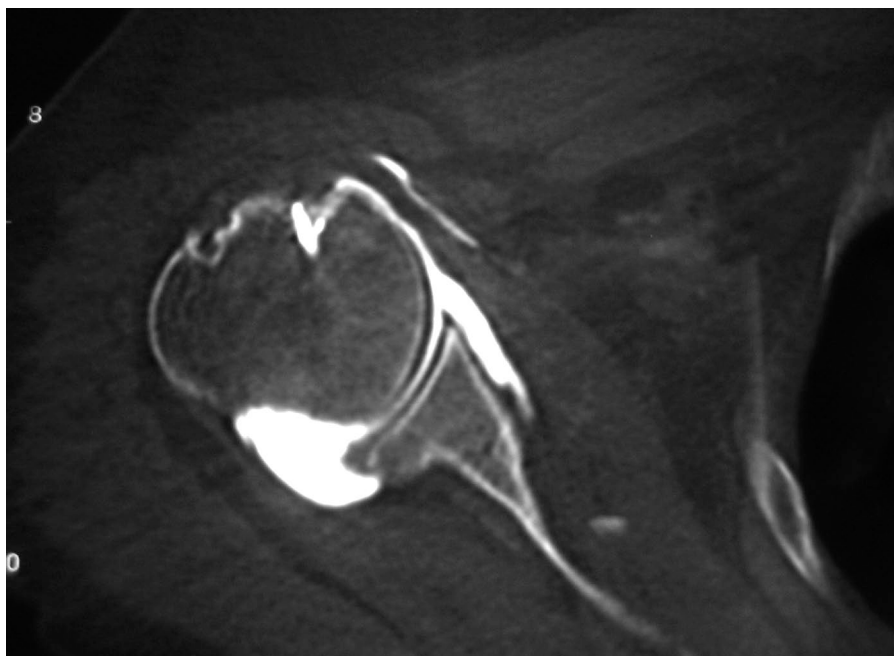


Fig. 4-B
Postoperative computed tomographic arthrogram of the same patient, made after arthroscopic subscapularis reconstruction, demonstrating reestablishment of the anatomic footprint for the subscapularis tendon.

96.4% postoperatively ($p < 0.001$). The mean UCLA score also showed significant improvement, from 16.2 points preoperatively to 32.1 points postoperatively ($p < 0.001$).

The patients also experienced significant overall improve-

ment in terms of pain, with the mean pain score improving from 5.9 points preoperatively to 13.5 points postoperatively ($p < 0.001$). Only one patient rated the shoulder pain as problematic.

The patients also had marked improvement in terms of objective shoulder function. The average passive external rotation decreased from 70.9° preoperatively to 65.3° postoperatively. In our experience, active external rotation is limited by pain in patients with subscapularis tears and repair permits a return to full active external rotation. We hypothesize that the arthroscopic repair of these lesions also results in substantially less trauma to the surrounding soft-tissue envelope than is experienced after open repair. As a result, an increase in active range of motion is observed. In the present study, the average active forward flexion increased from 145.6° preoperatively to 174.7° postoperatively (range, 150° to 180°) ($p = 0.005$). The average active external rotation in adduction improved from 50° (range, 10° to 80°) preoperatively to 60.3° (range, 10° to 80°) postoperatively ($p = 0.03$). The mean active internal rotation improved from the level of the sacrum preoperatively to the L1-L2 level postoperatively.

In order to assess subscapularis function, we compared the strength and pain during the modified lift-off and belly-press tests before and after surgery. The mean gain in force on the belly-press and lift-off tests postoperatively was 2 points. We believe that the clinical evaluation can demonstrate the structural integrity of the repair. Prior to arthroscopic repair of the subscapularis, five of our patients were unable to perform the lift-off test because of pain or stiffness that restricted internal rotation of the shoulder. At the time of the most recent follow-up evaluation, all of the patients were able to perform this test and to demonstrate improvement in the force generated during this examination. In four patients, strength continued to be classified as ≤ 3 on a 5-point scale. One of these patients had a subluxated biceps tendon, and another had a re-rupture of the superior two-thirds of the subscapularis repair. In the other two patients, the control computed tomographic arthrogram did not provide evidence of any abnormality that might explain the postoperative weakness.

The patients in the present series also demonstrated a marked increase on shoulder strength testing after subscapularis reconstruction. The average score for strength in abduction improved from 7.4 points (range, 0 to 12 points) before surgery to 15.6 points (range, 6 to 24 points) after arthroscopic reconstruction ($p < 0.001$).

Two patients had a structural failure of the subscapularis repair as documented with computed tomographic arthrography. The initial lesion in one patient was a rupture of the superior two-thirds of the subscapularis (a type-III tear according to our classification system), which was retracted to the glenoid. We suspect that this failure resulted from a technical error as only one suture anchor was used to reconstruct the subscapularis tendon. The lift-off test was mildly positive at the time of the most recent follow-up evaluation as the patient was able to lift the hand off of the back, but there was decreased strength against resistance as compared with the contralateral side. The belly-press test was negative, with normal strength as compared with the contralateral side and no pain. The overall clinical result for this patient was adequate, with an absolute Constant score of 83 points, a relative Con-

stant score of 93%, and a UCLA score of 30 points. The computed tomographic arthrogram showed a rupture of the superior two-thirds of the repair. The initial lesion in the second patient who had a re-ruptured tendon was a type-IV subscapularis tear with complete detachment from the insertion, retraction to the glenoid, and Goutallier stage-2 fatty infiltration. The postoperative belly-press and lift-off tests were positive. The postoperative computed tomographic arthrogram demonstrated a re-tear of the superior two-thirds of the tendon. At the time of the most recent follow-up evaluation for this patient, the absolute Constant score was 64 points, the relative Constant score was 71%, and the UCLA score was 26 points. In the case of one other patient, the computed tomographic arthrogram demonstrated cleavage of the superior third of the subscapularis tendon. The cleavage was not classified as a re-rupture, and the patient had an excellent clinical result.

There were two failures of biceps tenodesis in our series. One patient who had a normal biceps at the time of the subscapularis repair subsequently had development of subluxation of the long head of the biceps tendon without re-rupture of the subscapularis. We suspect that this may explain the unsatisfactory clinical result in this patient as reflected in a pain score of 7 points, an absolute Constant score of 54 points, a relative Constant score of 67.5%, and a UCLA score of 16. There were no infections. Two patients had development of a complex regional pain syndrome that resolved with medications and did not result in limited shoulder function at the time of latest follow-up.

Analysis of the plain radiographs that were made before and after surgery did not show any progression of osteoarthritis, and there was no evidence of hardware failure. Critical assessment of the computed tomographic arthrograms did not show progression of fatty infiltration in any of our patients. In addition, analysis of the subscapularis reconstruction on computed tomographic arthrograms demonstrated an intact repair of the tendon in fifteen patients (Figs. 4-A and 4-B). This result has been reported to be consistent with complete tendon healing²².

With the numbers studied, multiple-regression analysis of our data did not reveal any relationship between age at the time of surgery, the duration of symptoms prior to surgery, the follow-up period, and the ultimate clinical outcome. In addition, with the numbers available, Workers' Compensation status, the etiology of the tear (degenerative or traumatic), the size of the rupture, and the preoperative status of the biceps tendon did not have significant influence on the ultimate outcome in our study population. The impact of re-rupture and persistent fatty degeneration could not be determined on the basis of the data from our study.

Discussion

To our knowledge, the present study represents the largest reported series of patients who have been managed with arthroscopic repair of an isolated subscapularis tear. It is also the only study in which the structural integrity of

the arthroscopic repair of the subscapularis tendon has been evaluated on the basis of postoperative computed tomographic arthrograms.

Although several authors have reported on the clinical results of isolated subscapularis repair, the large variations in terms of the sample size, the follow-up period, the size of the tendon tear, and the degree of retraction have made direct comparisons difficult. In our review of the literature, we found only two studies evaluating the arthroscopic repair of subscapularis tears. Bennett reported on a series of eight patients with isolated subscapularis repairs who were followed for a minimum of two years⁷. The average postoperative Constant score was 74 points. However, the clinical evaluation of subscapularis function with use of either the lift-off or belly-press test was not reported. In addition, Bennett did not report on the structural integrity of the repairs postoperatively. As previously reported by Edwards et al., the strength component of the Constant score does not accurately reflect subscapularis dysfunction². Rather, it is a measure of overall shoulder strength as a function of the supraspinatus and deltoid muscles. Burkhart and Tehrani also reported on a series of eight patients who were managed with arthroscopic repair of an isolated subscapularis tear⁶. Although the early results were excellent in most of the patients, the short duration of follow-up (minimum, three months) did not permit definitive conclusions to be made.

Other investigators have reported satisfactory clinical outcomes after open repair of isolated subscapularis tears. The largest series, recently described by Edwards et al., was a multicenter study of eighty-four shoulders that had a mean postoperative Constant score of 79.5 points². The authors found that advanced fatty degeneration negatively influenced subscapularis function after repair. They also reported that concomitant biceps tenodesis, regardless of the presence of intraoperatively identified pathological changes, was associated with improved function and decreased pain after subscapularis repair. Gerber et al. reported on a series of sixteen patients who were followed for a minimum of two years after open subscapularis repair¹⁹. The authors found that eleven patients who had a positive preoperative lift-off test had normalization of the lift-off test after subscapularis repair. They also found that a delay in treatment resulted in poorer clinical outcomes. The average functional score for the shoulder was 82% of the average age and gender-matched normal value. Interestingly, 18.7% of patients had a deficit of external rotation of at least 30° and required arthroscopic release in order to restore function. Deutsch et al. noted similar improvement on the lift-off test after subscapularis repair as each of the thirteen patients in that study had a normalized lift-off test at the time of the most recent follow-up evaluation³.

One of the primary objectives of the present study was to evaluate the durability of anatomic reconstruction of the subscapularis. Several studies evaluating rotator cuff function after open and arthroscopic repair have demonstrated improved rotator cuff function in patients with intact rotator cuff repairs²²⁻²⁵. Those studies involved repairs of the superior

and posterosuperior aspects of the rotator cuff. However, we have no reason to believe that the functional implications of an intact rotator cuff repair in patients with subscapularis tears will not be similar. In fact, the present study supports the hypothesis that intact repairs will result in improved function since fifteen of the seventeen patients had an intact repair on the basis of the analysis of postoperative computed tomographic arthrograms as well as the overall significant improvements in subscapularis strength and function. This result compares favorably with that reported by Edwards et al., who reported that eleven of eighty-four shoulders had clinical or radiographic evidence of a failed repair². Prior to arthroscopic repair, five patients in our series were unable to perform the lift-off test because of pain or stiffness. Postoperatively, all patients were able to perform the lift-off test and significant increases in strength on the modified lift-off and belly-press tests were realized. In addition, our analysis of the belly-press and lift-off tests supports the observations made by other authors with regard to the usefulness of these tests for detecting lesions of the subscapularis clinically as sixteen of the seventeen tears in the present series were accurately diagnosed with the combination of these two maneuvers^{2,3,6,19}.

Unlike the findings of some other studies evaluating subscapularis reconstruction with use of open techniques, none of our patients experienced postoperative stiffness after the repair. In fact, all of the patients in the present study had significant increases in the active ranges of flexion, external rotation, and internal rotation. In the study by Gerber and colleagues, three of sixteen patients required arthroscopic release for the treatment of stiffness after subscapularis repair¹⁹. Similarly, in the study by Edwards et al., four of eighty-four shoulders had stiffness after open subscapularis repair, although all four shoulders were successfully treated with physical therapy². We suspect that the minimally invasive nature of arthroscopic subscapularis repair may result in less overall trauma to the soft-tissue envelope about the shoulder, resulting in fewer adhesions and a lower prevalence of postoperative stiffness.

One of the main weaknesses of the present study relates to the small sample size of patients. This fact might also explain why significant relationships between associated conditions we evaluated with multiple regression analysis were not identified.

Our classification system for subscapularis tears has been designed to be useful as a tool for diagnosis and as a guide for surgical treatment. As most previous studies and techniques for evaluating subscapularis tears were based on principles correlating with open tendon reconstruction, we believe that the prevalence of partial tears of the subscapularis tendon is underreported. In addition, current classification schemes do not differentiate between complete retracted tears of the subscapularis tendon that result in an eccentrically positioned humeral head and those with a completely congruent glenohumeral joint¹⁷. In our experience, this distinction is important because the outcomes between these two patient populations differ markedly. The patients with a retracted

subscapularis tendon who have also had development of static anterior subluxation of the humerus on the glenoid are not candidates for subscapularis repair and in our opinion should be managed with tendon transfer or arthroplasty. In conclusion, the results of the present study indicate that arthroscopic subscapularis repair can result in a durable rotator cuff repair with clinical results that are at least comparable with those of open repair techniques. ■

Laurent Lafosse, MD
Youri Reiland, MD

Stéphane Audebert, MD
Bruno Toussaint, MD
Alps Surgery Institute, Clinique General Annecy, 4 Ch Tour la Reine,
74000 Annecy, France

Reuben Gobezie, MD
Department of Orthopaedic Surgery, Case Western Reserve University
School of Medicine, 11100 Euclid Avenue, Cleveland, OH 44106. E-mail
address for R. Gobezie: reuben.gobezie@uhhospitals.org

Bernhard Jost, MD
Department of Orthopedics, University of Zurich, Balgrist, Forchstrasse
340, 8008 Zurich, Switzerland

References

- Gerber C, Krushell RJ. Isolated rupture of the tendon of the subscapularis muscle. Clinical features in 16 cases. *J Bone Joint Surg Br.* 1991;73:389-94.
- Edwards TB, Walch G, Sirveaux F, Mole D, Nove-Josserand L, Boulahia A, Neyton L, Szabo I, Lindgren B. Repair of tears of the subscapularis. *J Bone Joint Surg Am.* 2005;87:725-30.
- Deutsch A, Altchek DW, Veltri DM, Potter HG, Warren RF. Traumatic tears of the subscapularis tendon. Clinical diagnosis, magnetic resonance imaging findings, and operative treatment. *Am J Sports Med.* 1997;25:13-22.
- Nove-Josserand L, Levigne C, Noel E, Walch G. [Isolated lesions of the subscapularis muscle. Apropos of 21 cases]. *Rev Chir Orthop Reparatrice Appar Mot.* 1994;80:595-601. French.
- Thielemann FW, Kley U, Holz U. [Isolated injury of the subscapular muscle tendon]. *Sportverletz Sportschaden.* 1992;6:26-8. German.
- Burkhart SS, Tehrany AM. Arthroscopic subscapularis tendon repair: technique and preliminary results. *Arthroscopy.* 2002;18:454-63.
- Bennett WF. Arthroscopic repair of isolated subscapularis tears: a prospective cohort with 2- to 4-year follow-up. *Arthroscopy.* 2003;19:131-43.
- Lo IK, Burkhart SS. The etiology and assessment of subscapularis tendon tears: a case for subcoracoid impingement, the roller-wringer effect, and TUFF lesions of the subscapularis. *Arthroscopy.* 2003;19:1142-50.
- Bennett WF. Subscapularis, medial, and lateral head coracohumeral ligament insertion anatomy. Arthroscopic appearance and incidence of "hidden" rotator interval lesions. *Arthroscopy.* 2001;17:173-80.
- Bennett WF. Visualization of the anatomy of the rotator interval and bicipital sheath. *Arthroscopy.* 2001;17:107-11.
- Lo IK, Burkhart SS. The comma sign: an arthroscopic guide to the torn subscapularis tendon. *Arthroscopy.* 2003;19:334-7.
- Richards DP, Burkhart SS, Campbell SE. Relation between narrowed coracohumeral distance and subscapularis tears. *Arthroscopy.* 2005;21:1223-8.
- Richards DP, Burkhart SS, Lo IK. Subscapularis tears: arthroscopic repair techniques. *Orthop Clin North Am.* 2003;34:485-98.
- Constant CR, Murley AH. A clinical method of functional assessment of the shoulder. *Clin Orthop Relat Res.* 1987;214:160-4.
- Ellman H, Hunker G, Bayer M. Repair of the rotator cuff. End-result study of factors influencing reconstruction. *J Bone Joint Surg Am.* 1986;68:1136-44.
- Holtby R, Razmjou H. Accuracy of the Speed's and Yergason's tests in detecting biceps pathology and SLAP lesions: comparison with arthroscopic findings. *Arthroscopy.* 2004;20:231-6.
- Samilson RL, Prieto V. Dislocation arthropathy of the shoulder. *J Bone Joint Surg Am.* 1983;65:456-60.
- Goutallier D, Postel JM, Bernageau J, Lavau L, Voisin MC. Fatty muscle degeneration in cuff ruptures. Pre- and postoperative evaluation by CT scan. *Clin Orthop Relat Res.* 1994;304:78-83.
- Gerber C, Hersche O, Farron A. Isolated rupture of the subscapularis tendon. *J Bone Joint Surg Am.* 1996;78:1015-23.
- Morag Y, Jacobson JA, Shields G, Rajani R, Jamadar DA, Miller B, Hayes CW. MR arthrography of rotator interval, long head of the biceps brachii, and biceps pulley of the shoulder. *Radiology.* 2005;235:21-30.
- Bennett WF. Arthroscopic bicipital sheath repair: two-year follow-up with pulley lesions. *Arthroscopy.* 2004;20:964-73.
- Boileau P, Brassart N, Watkinson DJ, Carles M, Hatzidakis AM, Krishnan SG. Arthroscopic repair of full-thickness tears of the supraspinatus: does the tendon really heal? *J Bone Joint Surg Am.* 2005;87:1229-40.
- Gazielly DF, Gleyze P, Montagnon C, Bruyere G, Prallet B. [Functional and anatomical results after surgical treatment of ruptures of the rotator cuff. 1: Preoperative functional and anatomical evaluation of ruptures of the rotator cuff]. *Rev Chir Orthop Reparatrice Appar Mot.* 1995;81:8-16. French.
- Harryman DT 2nd, Mack LA, Wang KY, Jackins SE, Richardson ML, Matsen FA 3rd. Repairs of the rotator cuff. Correlation of functional results with integrity of the cuff. *J Bone Joint Surg Am.* 1991;73:982-9.
- Galatz LM, Ball CM, Teefey SA, Middleton WD, Yamaguchi K. The outcome and repair integrity of completely arthroscopically repaired large and massive rotator cuff tears. *J Bone Joint Surg Am.* 2004;86:219-24.