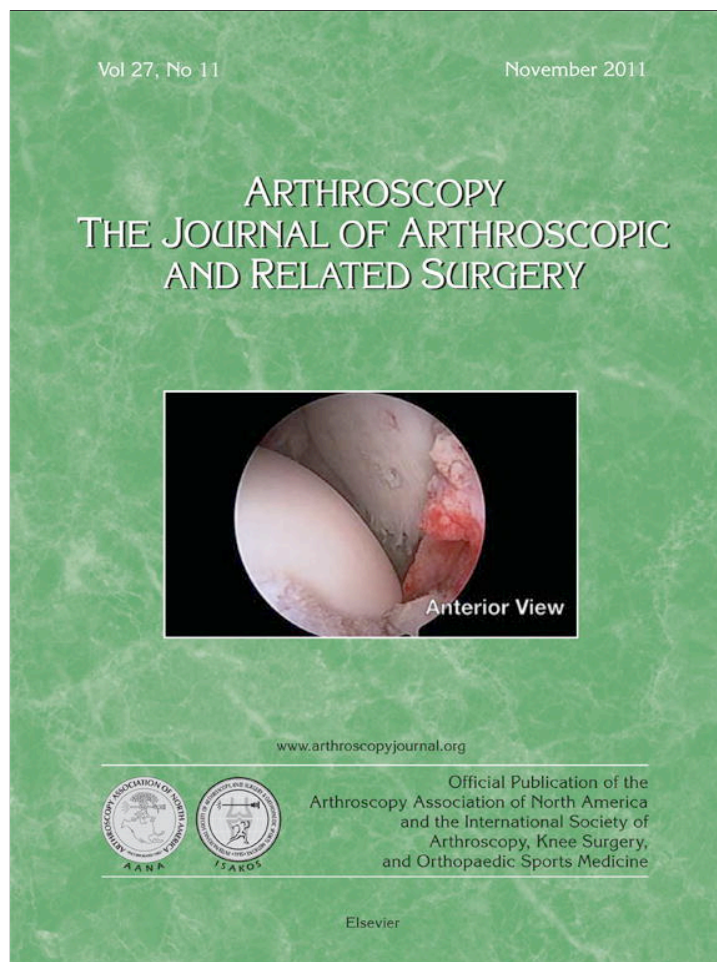


Provided for non-commercial research and education use.
Not for reproduction, distribution or commercial use.



This article appeared in a journal published by Elsevier. The attached copy is furnished to the author for internal non-commercial research and education use, including for instruction at the authors institution and sharing with colleagues.

Other uses, including reproduction and distribution, or selling or licensing copies, or posting to personal, institutional or third party websites are prohibited.

In most cases authors are permitted to post their version of the article (e.g. in Word or Tex form) to their personal website or institutional repository. Authors requiring further information regarding Elsevier's archiving and manuscript policies are encouraged to visit:

<http://www.elsevier.com/copyright>

Technical Note With Video Illustration

All-Arthroscopic Biologic Total Shoulder Resurfacing

Reuben Gobezie, M.D., Christopher J. Lenarz, M.D., John Paul Wanner, B.S., and Jonathan J. Streit, M.D.

Abstract: The treatment of advanced, bipolar glenohumeral osteoarthritis in the young patient is particularly challenging because of the expected failure of a traditional shoulder arthroplasty within the patient's lifetime. We have had early success performing osteochondral allograft resurfacing of the humeral head articular surface and glenoid articular surface, and we describe a new all-arthroscopic technique for performing this procedure. In the context of our new procedure, we have reviewed the available literature on the topic of biologic resurfacing with osteochondral allograft and have provided an overview of the relevant findings. Although only short-term follow-up data are available, our results in young patients have been promising in terms of regained motion, minimal pain, and accelerated rehabilitation. We believe that this new arthroscopic biologic shoulder resurfacing technique has the potential to be superior to other available treatments for this patient population because it preserves bone stock, limits damage to surrounding structures, and allows for early rehabilitation. Although longer-term follow-up is needed, early results have been greatly encouraging.

The treatment of large, bipolar osteochondral lesions and osteoarthrosis of the glenohumeral joint in the young, active patient has long been a challenge for even the most skilled orthopaedic surgeon (Fig 1). Despite its success in relieving pain and restoring function,¹ total shoulder arthroplasty (TSA) has significant drawbacks for the young patient, which include glenoid loosening¹ because of osteolysis,² the

production of polyethylene wear particles,² and the need for revision surgery.¹ Because glenohumeral arthrosthrosis may result in significant pain, loss of function, and diminished quality of life,³ the development of surgical treatments that address the issues specific to the young patient with shoulder arthritis remains an area of active research and clinical need.

We describe a novel technique for the treatment of shoulder arthritis and larger focal defects in the younger patient: an all-arthroscopic osteochondral total shoulder resurfacing using fresh osteochondral allografts of the humeral head and medial tibial condyle or distal tibial plafond, performed entirely through the rotator interval. In addition to providing a biologic resurfacing of the damaged glenohumeral joint, which preserves bone stock and leaves open the possibility of later conversion to standard TSA, our arthroscopic approach limits damage to surrounding structures including the subscapularis, thereby offering the potential to significantly decrease the morbidity and rehabilitation required after surgery as compared with standard TSA.

From the Case Shoulder & Elbow Service, Case Western Reserve University–University Hospitals of Cleveland (R.G., C.J.L., J.P.W.), Cleveland; and Case Western Reserve University–University Hospitals of Cleveland (J.J.S.), Cleveland, Ohio, U.S.A.

R.G. is a consultant for and receives support from Arthrex, Naples, Florida, and Tournier, Edina, Minnesota.

Received April 18, 2011; accepted July 8, 2011.

Address correspondence to Reuben Gobezie, M.D., 11100 Euclid Ave, Cleveland, OH 44106, U.S.A. E-mail: clevelandshoulder@gmail.com

© 2011 by the Arthroscopy Association of North America

0749-8063/11242/\$36.00

doi:10.1016/j.arthro.2011.07.008

<p>Note: To access the video accompanying this report, visit the November issue of <i>Arthroscopy</i> at www.arthroscopyjournal.org.</p>
--

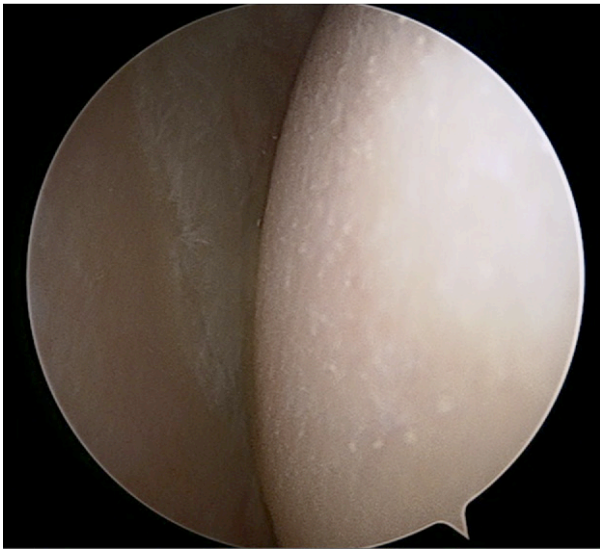

FIGURE 1. Arthroscopic view of right shoulder, with patient in beach-chair position, through posterior portal. Bipolar osteochondral defects of the humeral head and glenoid were found on initial arthroscopic examination in a patient who underwent arthroscopic biologic shoulder resurfacing. Such large defects have historically been difficult to treat in younger patients.

SURGICAL TECHNIQUE

Joint Preparation

The patient is placed in the beach-chair position under general anesthesia, and a pneumatic arm holder is used for positioning of the upper extremity (Video 1, available at www.arthroscopyjournal.org). The arm is prepared and draped in standard fashion, and appropriate antibiotic prophylaxis is administered before incision. A standard posterior portal is then used to introduce the inflow cannula into the glenohumeral joint, and an anterior portal is placed through the rotator interval by the outside-in technique. The skin incision for the anterior portal placement will need to measure 20 to 25 mm to allow for the passage of instrumentation and allograft. An initial debridement of the glenohumeral joint is performed. The entire rotator interval is then resected with an arthroscopic shaving device to enable instrumentation of the glenohumeral joint.

Humeral Head Preparation

A 25-mm targeting guide is inserted through the anterior portal and centered over the articular surface of the humeral head, and a guide sleeve is inserted to localize the area for the lateral skin incision, which is made large enough to receive the cannula. A 2.4-mm

guide pin is then drilled through the humerus until it passes through the humeral head. The guide pin is secured intra-articularly with a grasper, and a 5.5-mm cannulated drill is then advanced over the guide pin and into the subchondral bone of the humeral head. The reamer is removed, with care taken not to remove the 2.4-mm guide pin. A transhumeral sleeve is passed over the portal dilator until it is visualized inside the glenohumeral joint. By use of a round bur, the subchondral bone around the transhumeral sleeve is removed to a depth of 2 to 3 mm at a diameter of 10 mm to allow retrograde reaming of the humeral head. Depending on the size of the humeral head, a 20- or 25-mm retrograde reamer is inserted into the glenohumeral joint through the anterior portal. The retro-pin is then connected to the retrograde reamer, the transhumeral sleeve is withdrawn 5 mm into the humerus, and the humeral head is reamed in a retrograde fashion by running the reamer on forward and pulling the reamer laterally, pressing it against the humeral head articular surface. This is continued until the reamer rim has made contact with the humeral head circumferentially. These steps can then be repeated with the 30-mm retrograde reamer to increase the size of the reamed area. After this stage of the procedure has been completed, the transhumeral sleeve is left in place for glenoid instrumentation.

Glenoid Preparation

The glenoid aiming guide is introduced into the joint through the anterior portal, and the aiming guide is centered over the bare spot of the glenoid. Through the transhumeral sleeve, a 2.4-mm pin is used to create a 10-mm-deep centering hole. The retro-pin is placed through the transhumeral sleeve, and a 20-mm antegrade reamer is introduced through the anterior portal. The glenoid is then reamed until the rim contacts the glenoid surface circumferentially (Fig 2). The joint is debrided of any debris from reaming, and the reamed surfaces are inspected and cleared of any soft tissue that could interfere with allograft placement.

Graft Preparation

Our procedure requires osteoarticular allografts taken from a cadaveric humeral head and medial tibial condyle. We have used the medial tibial condylar surface because it is concave and appears to best re-create the shape of the native glenoid.

The glenoid allograft is prepared first, and this part of the procedure may be performed before incision if desired. Fresh, cold-stored tibial plateau allograft is

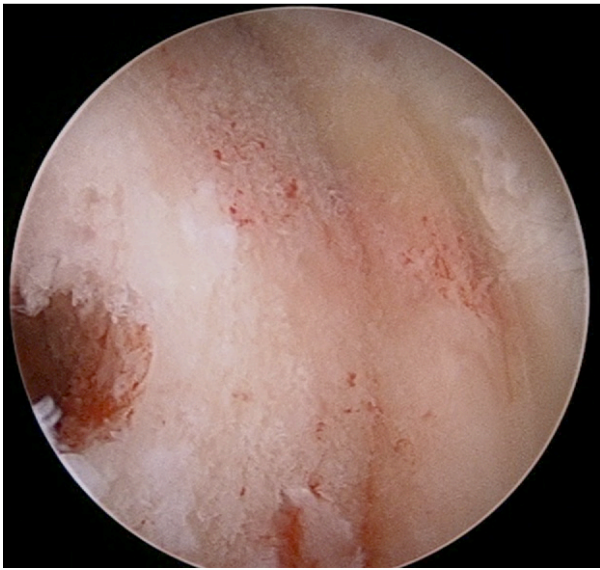

FIGURE 2. Arthroscopic view of right shoulder, with patient in beach-chair position, through posterior portal. Placement of glenoid and humeral allografts may be performed arthroscopically with the use of novel instrumentation. A glenoid defect has been reamed arthroscopically with instrumentation passed through the humeral head, creating a site for placement of a tibial condyle allograft.

firmly fixed to the Osteochondral Autograft Transfer System (OATS) platform (Arthrex, Naples, FL), and a coring reamer guide is centered over the portion of the articular surface chosen by the surgeon for glenoid resurfacing (Fig 3). A surgical assistant should securely hold the allograft with a pair of towel clips to help prevent torque, which might cause a change in position of the graft. The core reamer is taken to a minimum depth of 10 mm, and this core is removed from the tibial plateau. The core is placed in the 5-mm-deep cutting guide with the articular surface facing into the guide, and an oscillating saw is then used to cut the allograft to a thickness of 5 mm.

The selection and coring procedure is repeated for the humeral head allograft. In contrast to preparation of the glenoid component, preparation of the humeral head allograft should not be performed until completion of arthroscopic reaming of the patient's humeral articular surface so that the appropriate allograft diameter may be selected. Once this has been established, a 25- to 35-mm osteochondral allograft is harvested from the cadaveric humeral head by the same technique that was used for glenoid surface preparation. After this has been completed, a small drill hole is made through the center of the humeral head allograft to allow passage of a No. 2 FiberWire suture

(Arthrex) through the allograft. A large knot is then tied on the articular side of the graft approximately 3 inches from the end of the suture. This suture will be fed through the transhumeral portal to allow pulling of the allograft back onto the humerus.

Graft Implantation

The glenoid graft is placed into the glenoid inserter such that the articular surface is facing the inserter plate and the cancellous bone is visible. The construct is then inserted through the anterior portal and positioned over the reamed glenoid surface. The glenoid retainer is removed, and alignment of the graft with the reamed surface is verified. The retro-pin is then inserted through the transhumeral sleeve, and the allograft is lightly tapped into position with a mallet until approximately 80% of the graft is seated. A graft impactor inserted through the anterior portal is used to completely seat the graft. Three chondral darts are then placed through the transhumeral portal and into the grafted glenoid surface, securing it into place.

For placement of the humeral head graft, a Nitinol wire is inserted through the transhumeral portal and retrieved through the anterior portal. The No. 2 FiberWire suture (Arthrex) is then fed through the loop at the end of the Nitinol wire, the wire is pulled back through the transhumeral portal, and the suture is fed out the lateral portal to allow for traction of the graft onto the reaming site (Fig 4). The humeral head allograft is inserted through the anterior portal, positioned over the reamed surface, and lightly seated.

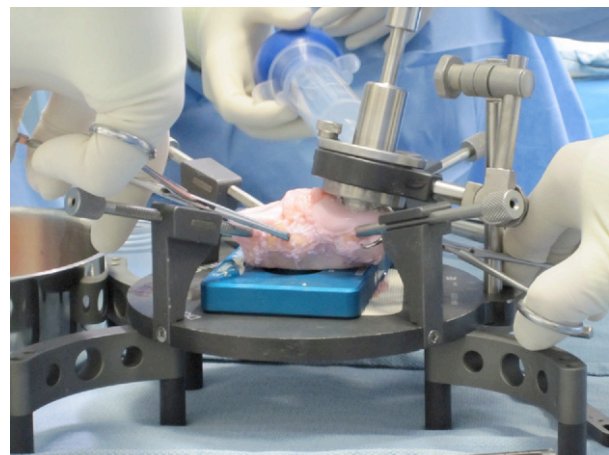


FIGURE 3. Arthroscopic resurfacing of diseased glenoid is accomplished by use of medial tibial condyle allograft, which is prepared and cut for eventual glenoid replacement before the procedure is started.

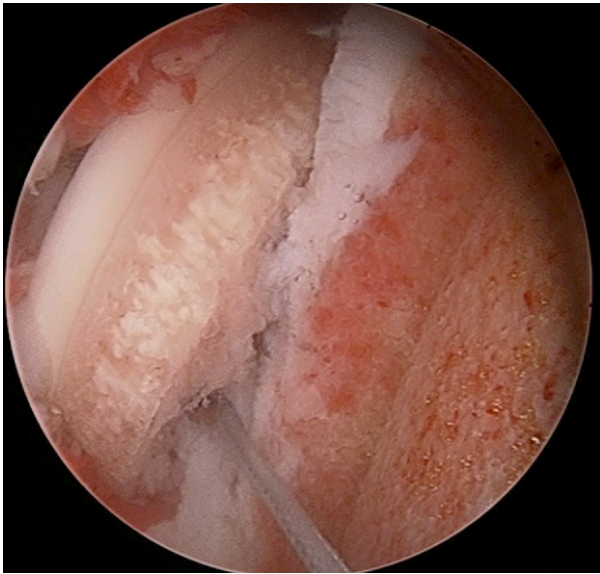


FIGURE 4. Arthroscopic view of right shoulder, with patient in beach-chair position, through posterior portal. Humeral resurfacing is accomplished after reverse reaming arthroscopically over a trans-humeral guide pin. The allograft humeral head is moved into position with a traction suture, creating a humeral head articular surface that is free of defects.

Additional digital pressure for seating may be applied through the anterior portal, or pressure may be applied by moving the shoulder through a range of motion to compress the humeral allograft against the glenoid. The glenoid graft is then secured into place by use of 3 or 4 chondral darts inserted through a Neviaser portal (Fig 5), and the No. 2 FiberWire is retrieved through the anterior portal. Wound closure then proceeds in the standard fashion, and the extremity is immobilized in a sling before the patient leaves the operative suite.

DISCUSSION

Osteochondral lesions of the glenohumeral joint may be caused by trauma, infection, avascular necrosis, osteochondritis dissecans, osteoarthritis, inflammatory arthritides, idiopathic chondrolysis, rotator cuff arthropathy, or iatrogenic injury, which may include the effects of intra-articular pain pumps, radio-frequency devices,⁴⁻⁷ and prominent anchors.⁸ Humeral head articular cartilage is 1.2 to 1.3 mm thick centrally and less than 1 mm thick peripherally,⁸ making it especially prone to injury when compared with the thicker articular cartilage found elsewhere in the body.¹ The incidence of symptomatic Outerbridge

grade II through IV cartilage injuries found at the time of arthroscopy has been reported at between 5% and 17%,⁹ and many more chondral lesions are found incidentally.¹ At present, the natural history of chondral lesions of the glenohumeral joint is unknown, although it is believed that unipolar lesions will eventually progress to become bipolar lesions.¹

Because of unacceptably high failure rates,⁸ currently, fewer than 10% of TSA procedures are performed in patients aged younger than 50 years,¹⁰ which presents a treatment dilemma for the young patient with advanced disease. Arthroscopic debridement has been effective in delaying or preventing the need for shoulder arthroplasty, although Van Thiel et al.¹¹ cited the presence of grade 4 bipolar disease, joint space narrowing to less than 2 mm, and the presence of large osteophytes to be risk factors for failure of this procedure. A capsular release added to this procedure has also shown good results in a small cohort, although outcomes were better in patients with less-advanced disease.¹² Microfracture, autologous osteochondral transfers (OATS), and autologous chondrocyte implantation are also options for smaller lesions. Unipolar osteochondral allograft and biologic resurfacing are also options, although currently, there is no treatment suitable for young, active patients with large, high-grade osteochondral lesions that enjoys widespread success.

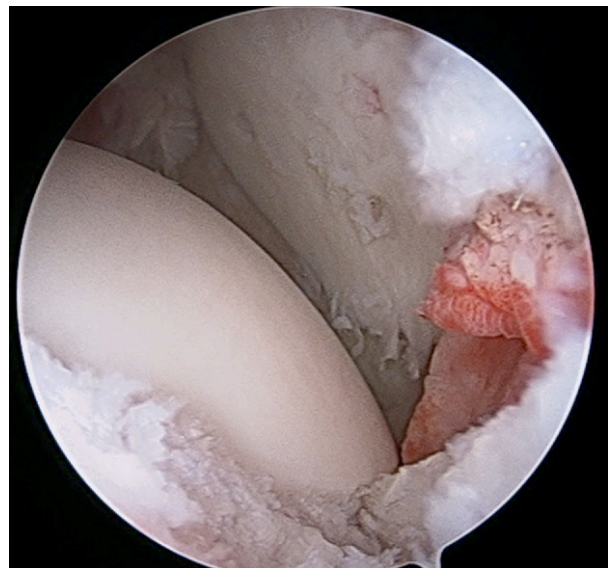


FIGURE 5. Arthroscopic view of right shoulder, with patient in beach-chair position, through anterior portal. A defect-free articular surface has been created by resurfacing the humerus and glenoid. Chondral darts have been used to secure the tibial condyle graft within the native glenoid.

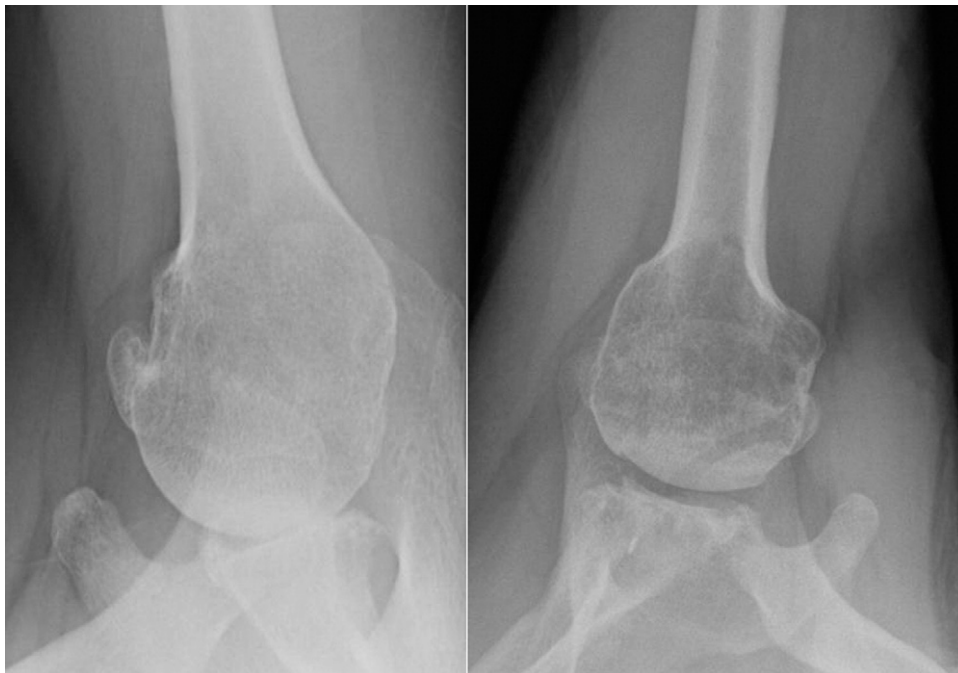

FIGURE 6. Axillary radiographs taken preoperatively (left) and postoperatively (right) in a 53-year-old patient show the re-creation of the glenohumeral joint space and a smooth articular surface. The grafts are beginning to incorporate into the surrounding host bone.

To date, we have performed our novel procedure in 10 patients. Four patients with a mean age of 47 years have been followed up for at least 1 month postoperatively. The mean visual analog scale pain score has improved from 8.7 to 1.5, the mean American Shoulder and Elbow Surgeons score has improved from 57 to 89, and all grafts have remained stable without signs of resorption (Fig 6). Range of motion has also been noted to improve considerably.

The use of an all-arthroscopic technique for the insertion of our allograft components through the rotator interval leaves the subscapularis muscle undisturbed and altogether avoids the complication of rupture. Skendzel and Sekiya¹³ recently described a similar insertion technique for glenoid allograft used to address anterior bone loss and cited faster rehabilitation and elimination of the risk of reattachment failure as reasons for using this technique. On the basis of our short-term follow-up data, we agree with these authors that leaving the subscapularis undisturbed promotes early rehabilitation.

Our novel technique has built on decades of investigation into the possibilities of biologic joint resurfacing. Successful osteochondral allograft and autograft procedures have been reported for the treatment of unipolar lesions of the glenohumeral joint, with autograft procedures having the unfortunate downsides of donor-site morbidity¹⁴ and increased contact pressures in the joint from which graft has been harvested.¹⁵

Scheibel et al.¹⁴ reported the results of 8 patients with grade IV lesions of the humeral head treated with osteochondral autograft from the knee, with good results at a mean follow-up of 32.6 months, although donor-site morbidity was a problem in at least 2 patients. Implantation of allograft plugs up to 40 mm in diameter for the treatment of humeral head lesions has been successful and is described in case series and case reports.¹⁶⁻²⁰ Recently, open biologic TSA using a press-fit humeral head was reported with some success in 7 patients having bipolar glenohumeral lesions as a result of postarthroscopic glenohumeral chondrolysis, although the authors noted 2 failures, with 1 of these being converted to a standard TSA.²¹

An understanding of the durability of these new biologic implants is also important for the management of surgeon and patient expectations. A series of osteochondral grafts, which included 65 fresh tibial allografts and 72 fresh femoral allografts, showed a survival rate of 85% at 10 years when used in the knee,^{22,23} with the tibial allografts from 1 of these reports even showing a 43% survival rate at 20 years.²³ Use of osteochondral allograft in the shoulder, which is a non-weight-bearing joint, may reasonably be expected to show even better survival.²⁴ The use of osteochondral allografts in the setting of altered bone metabolism because of smoking, chronic steroid use, or use of nonsteroidal anti-inflammatory medications has not yet been studied.²⁵ Despite standardized and

regulated harvesting practices, implantation of osteochondral allografts has been reported to have led to bacterial infection,²⁶ and it is recommended that the graft be removed immediately when even superficial postoperative infection occurs, because of the presence of necrotic tissue, which can rapidly become a nidus for recurrence.²⁵ In addition, patients should be counseled regarding the risks of disease transmission, because there have been 3 reported cases of human immunodeficiency virus transmission, 2 cases of hepatitis B transmission, and 1 case of hepatitis C transmission after allograft transplantation.²⁷ Currently, the risk of human immunodeficiency virus transmission is considered 1 in 1 million.²⁷

We have had early success performing osteochondral allograft resurfacing of the humeral head articular surface and glenoid articular surface as a bipolar graft and describe a new all-arthroscopic technique for performing this procedure in young patients with advanced glenohumeral osteoarthritis. We believe that this technique has potential to be superior to other available treatments for this patient population because it preserves bone stock, limits damage to surrounding structures, and allows for early rehabilitation. Longer-term follow-up will be needed to better understand the true benefits of this procedure.

REFERENCES

- Cole BJ, Yanke A, Provencher MT. Nonarthroplasty alternatives for the treatment of glenohumeral arthritis. *J Shoulder Elbow Surg* 2007;16:231S-240S.
- Nicholson GP, Goldstein JL, Romeo AA, et al. Lateral meniscus allograft biologic glenoid arthroplasty in total shoulder arthroplasty for young shoulders with degenerative joint disease. *J Shoulder Elbow Surg* 2007;16:S261-S266 (Suppl).
- Silverstein E, Leger R, Shea KP. The use of intra-articular hyaluron G-F 20 in the treatment of symptomatic osteoarthritis of the shoulder: A preliminary study. *Am J Sports Med* 2007;35:979-985.
- Good CR, Shindle MK, Kelly BT, Wanich T, Warren RF. Glenohumeral chondrolysis after shoulder arthroscopy with thermal capsulorrhaphy. *Arthroscopy* 2007;23:791.e1-791.e5. Available online at www.arthroscopyjournal.org.
- Levine WN, Clark AM Jr, D'Alessandro DF, Yamaguchi K. Chondrolysis following arthroscopic thermal capsulorrhaphy to treat shoulder instability. A report of two cases. *J Bone Joint Surg Am* 2005;87:616-621.
- Lu Y, Edwards RB III, Nho S, Heiner JP, Cole BJ, Markel MD. Thermal chondroplasty with bipolar and monopolar radiofrequency energy: Effect of treatment time on chondrocyte death and surface contouring. *Arthroscopy* 2002;18:779-788.
- Ryan A, Bertone AL, Kaeding CC, Backstrom KC, Weisbrode SE. The effects of radiofrequency energy treatment on chondrocytes and matrix of fibrillated articular cartilage. *Am J Sports Med* 2003;31:386-391.
- Elser F, Dewing CB, Millett PJ. Chondral and osteochondral lesions of the humerus: Diagnosis and management. *Oper Tech Sports Med* 2008;16:178-186.
- Paley KJ, Jobe FW, Pink MM, Kvitne RS, ElAttrache NS. Arthroscopic findings in the overhand throwing athlete: Evidence for posterior internal impingement of the rotator cuff. *Arthroscopy* 2000;16:35-40.
- Adams JE, Sperling JW, Hoskin TL, Melton LJ III, Cofield RH. Shoulder arthroplasty in Olmsted County, Minnesota, 1976-2000: A population-based study. *J Shoulder Elbow Surg* 2006;15:50-55.
- Van Thiel GS, Sheehan S, Frank RM, et al. Retrospective analysis of arthroscopic management of glenohumeral degenerative disease. *Arthroscopy* 2010;26:1451-1455.
- Richards DP, Burkhart SS. Arthroscopic debridement and capsular release for glenohumeral osteoarthritis. *Arthroscopy* 2007;23:1019-1022.
- Skendzel JG, Sekiya JK. Arthroscopic glenoid osteochondral allograft reconstruction without subscapularis takedown: Technique and literature review. *Arthroscopy* 2011;27:129-135.
- Scheibel M, Bartl C, Magosch P, Lichtenberg S, Habermeyer P. Osteochondral autologous transplantation for the treatment of full-thickness articular cartilage defects of the shoulder. *J Bone Joint Surg Br* 2004;86:991-997.
- Garretson RB III, Katolik LI, Verma N, Beck PR, Bach BR, Cole BJ. Contact pressure at osteochondral donor sites in the patellofemoral joint. *Am J Sports Med* 2004;32:967-974.
- Bugbee WD, Convery FR. Osteochondral allograft transplantation. *Clin Sports Med* 1999;18:67-75.
- Chapovsky F, Kelly JD IV. Osteochondral allograft transplantation for treatment of glenohumeral instability. *Arthroscopy* 2005;21:1007.
- Convery FR, Meyers MH, Akeson WH. Fresh osteochondral allografting of the femoral condyle. *Clin Orthop Relat Res* 1991:139-145.
- Miniaci A, Gish MW. Management of anterior glenohumeral instability associated with large Hill-Sachs defects. *Tech Shoulder Elbow Surg* 2004;5:170-175.
- Gerber C, Lambert SM. Allograft reconstruction of segmental defects of the humeral head for the treatment of chronic locked posterior dislocation of the shoulder. *J Bone Joint Surg Am* 1996;78:376-382.
- McNickle AG, L'Heureux DR, Provencher MT, Romeo AA, Cole BJ. Postsurgical glenohumeral arthritis in young adults. *Am J Sports Med* 2009;37:1784-1791.
- Aubin PP, Cheah HK, Davis AM, Gross AE. Long-term followup of fresh femoral osteochondral allografts for posttraumatic knee defects. *Clin Orthop Relat Res* 2001:S318-S327 (Suppl).
- Shasha N, Krywulak S, Backstein D, Pressman A, Gross AE. Long-term follow-up of fresh tibial osteochondral allografts for failed tibial plateau fractures. *J Bone Joint Surg Am* 2003;85:33-39 (Suppl 2).
- Johnson DL, Warner JJ. Osteochondritis dissecans of the humeral head: Treatment with a matched osteochondral allograft. *J Shoulder Elbow Surg* 1997;6:160-163.
- Görtz S, Ho A, Bugbee W. Fresh osteochondral allograft transplantation for cartilage lesions in the knee. Presented at the Annual Meeting of the American Academy of Orthopaedic Surgeons, Chicago, IL, March 22-26, 2006.
- Centers for Disease Control and Prevention. Update: Allograft associated bacterial infections. *MMWR Morb Mortal Wkly Rep* 2002;51:207-210.
- Mroz TE, Joyce MJ, Steinmetz MP, Lieberman IH, Wang JC. Musculoskeletal allograft risks and recalls in the United States. *J Am Acad Orthop Surg* 2008;16:559-565.