

# Progressive Osteolysis and Surface Chondrolysis of the Proximal Humerus Following Influenza Vaccination

PATRICK J. MESSERSCHMITT, MD; FADI W. ABDUL-KARIM, MD; JOSEPH P. IANNOTTI, MD, PHD;  
REUBEN G. GOBEZIE, MD

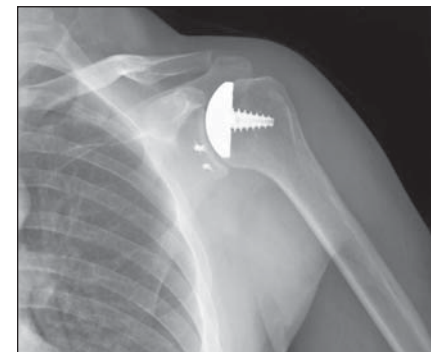
## abstract

Full article available online at [ORTHOSuperSite.com](http://ORTHOSuperSite.com). Search: 20120123-26

Influenza vaccination is a common annual event among individuals in the United States. Complications, although infrequent, are usually mild and self-limiting. This article describes the case of a 46-year-old man who experienced progressive osteolysis and surface chondrolysis of the proximal humerus following routine influenza vaccination.

The patient presented with shoulder pain and limited range of motion 3 weeks following vaccination in the deltoid area. No skin changes were noted, inflammatory markers were normal, and the patient's pain and disability persisted despite nonsteroidal anti-inflammatory drugs and occupational therapy. Plain radiographs revealed a small lytic area involving the greater tuberosity of the humeral head. Magnetic resonance imaging (MRI) showed abnormal uptake and cystic changes involving the greater tuberosity of the humeral head; repeat MRI at 5 months showed progression in the cystic changes. Diagnostic arthroscopy of the shoulder revealed a hyperemic joint capsule and extensive, full-thickness chondrolysis of the humeral head. Cystic biopsy demonstrated inflammatory cells and granulation tissue, consistent with foreign body response. Cultures were negative. Surgical debridement of the cystic areas and resurfacing of the humeral head yielded a good outcome.

To our knowledge, this is the first reported complication of influenza vaccination requiring surgical intervention. Physicians need to be aware of the potential for osteolysis and chondrolysis, which may require aggressive forms of management.



**Figure:** Postoperative anteroposterior radiograph of the left shoulder showing humeral head arthroplasty. The osteolytic area involving the greater tuberosity of the humeral head resolves as the area fills in with bone.

*Dr Messerschmitt is from the Division of Hand, Upper Extremity & Microvascular Surgery, Department of Orthopaedic Surgery, Warren Alpert Medical School, Brown University, Providence, Rhode Island; Dr Abdul-Karim is from the Department of Pathology, and Dr Gobezie is from the Department of Orthopaedic Surgery, Case Western Reserve University, University Hospitals Case Medical Center, and Dr Iannotti is from the Department of Orthopaedic Surgery, Cleveland Clinic Foundation, Cleveland, Ohio.*

*Drs Messerschmitt, Abdul-Karim, Iannotti, and Gobezie have no relevant financial relationships to disclose.*

*Correspondence should be addressed to: Patrick J. Messerschmitt, MD, Division of Hand, Upper Extremity & Microvascular Surgery, Department of Orthopaedic Surgery, Warren Alpert Medical School, Brown University, Medical Office Center/Ste 200, 2 Dudley St, Providence, RI 02905 (pmesserschmittmd@gmail.com).*

*doi: 10.3928/01477447-20120123-26*

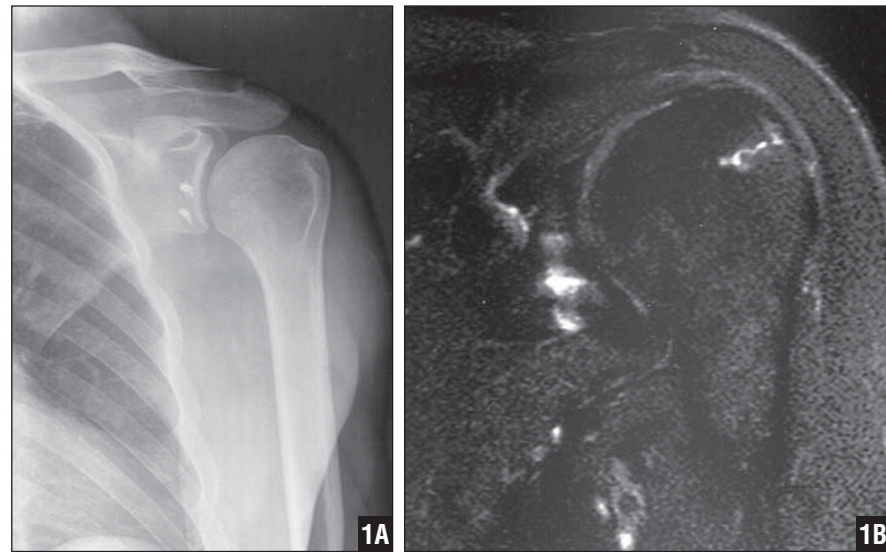
Influenza vaccination is a common annual event among individuals in the United States. Complications, although infrequent, are usually mild and self-limiting. Following immunization, localized swelling, erythema, and pain in and around the injection site can occur and generally resolves in 1 to 2 days.<sup>1</sup> Shoulder pain progressing to the point of limited range of motion (ROM) and dysfunction following influenza vaccination have been reported and resolved with subacromial injection and physical therapy.<sup>2</sup> This article describes the first reported case of progressive osteolysis and surface chondrolysis of the proximal humerus following routine influenza vaccination that required surgical intervention.

### CASE REPORT

A 46-year-old man presented with left shoulder pain of 3 weeks' duration, which started immediately following an influenza vaccination in the left deltoid area. He reported no recent trauma, and the left shoulder had been asymptomatic preceding the vaccination, including a complete recovery from an open Bankart repair performed 13 years previously. The patient was healthy, with no medical comorbidities, and reported no previous corticosteroid use or alcohol abuse.

The vaccination was given with a 1-inch needle and placed into the left deltoid muscle in a lateral and proximal position, approximately 2 cm distal to the lateral aspect of the acromion. No immediate vaccination complications or infectious changes of the skin occurred. Left shoulder discomfort began a few days following the injection, progressively worsened, and partially subsided with nonsteroidal anti-inflammatory drugs (NSAIDs). The pain was localized to the anterior shoulder joint and was exacerbated with overhead activities.

Initial examination demonstrated a healthy-appearing man with no excessive muscle mass or subcutaneous fat surrounding the shoulder girdle. No changes of the skin were noted. Forward flexion



**Figure 1:** Anteroposterior radiograph of the left shoulder with external rotation. Good shoulder alignment with no obvious osteoarthritic changes of the humeral head articular surface. A small lytic area appears to involve the greater tuberosity of humeral head. Suture anchors from prior Bankart repair are intact (A). Coronal T2-weighted magnetic resonance imaging of the left shoulder showing small area of abnormal signal enhancement laterally in the greater tuberosity of the humeral head (B).

(150), external rotation (35°), and internal rotation (L2) were limited compared with the unaffected side (160°, 45°, T7, respectively). He had tenderness over the biceps tendon and deltoid laterally. O'Brien's and Speed's tests were positive. Plain radiographs revealed a small lytic area involving the greater tuberosity of the humeral head and surgical changes relating to Bankart repair (Figure 1A). Magnetic resonance imaging (MRI) revealed abnormal uptake and cystic changes involving the greater tuberosity of the humeral head (Figure 1B). No bone marrow changes occurred, consistent with early osteonecrosis of the humeral head (Figure 1B). Bone scan revealed isolated increased signal intensity involving the lateral aspect of the humeral head.

Conservative management over the next 5 months, including NSAIDs and occupational therapy, was unsuccessful. No cortisone injections were administered. The patient's left shoulder pain and disability worsened, and he was unable to return to normal activities of daily living. Follow-up revealed continued tenderness over the biceps tendon and further limita-

tion on internal rotation to L5. Laboratory results, including white blood cell count, C-reactive protein, and erythrocyte sedimentation rate, were normal. Repeat MRI of the left shoulder revealed progression of the cystic changes and abnormal signal uptake involving the greater tuberosity of the humeral head (Figure 2).

The patient's clinical dysfunction was worsening, and the greater tuberosity cyst was rapidly enlarging despite conservative measures. Surgical intervention was recommended. The patient underwent diagnostic arthroscopy of the shoulder and open biopsy of the cystic area involving the greater tuberosity. Arthroscopy revealed a hyperemic joint capsule and extensive chondrolysis involving approximately 50% of the articular surface of the humeral head with a central, full-thickness defect. Hyperemia of the exposed subchondral bone was noted. The glenoid demonstrated minimal chondral fraying. The biceps tendon was intact but hyperemic and consistent with tenosynovitis. No intra-articular interventions were performed during this initial surgical procedure except thorough arthroscopic irri-

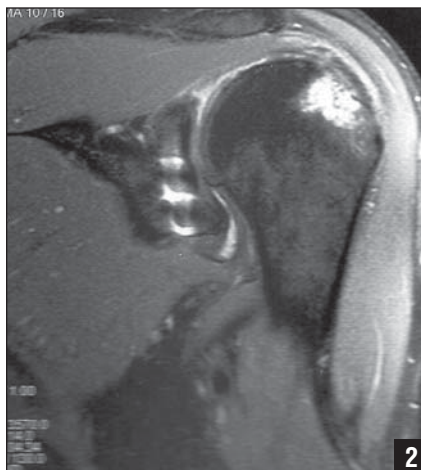
gation. During open biopsy of the humeral greater tuberosity, the lateral cortex was softened, and when opened, a serosanguinous fluid exited. The area was thoroughly debrided, and bone grafting was initially delayed due to concern for possible infection because the intraoperative frozen section was inconclusive.

The cultures obtained intraoperatively were negative for infection and showed no histological evidence of osteonecrosis. Pathological examination of surgical specimens demonstrated inflammatory cells and granulation tissue, consistent with reactive disease or foreign-body response (Figure 3A). The progressive humeral lesion and inflammatory component was attributed to a reaction following the influenza vaccination, most likely given intraosseously. In addition, the extensive humeral head chondrolysis and biceps tendonitis were likely an inflammatory reaction to the injection and contributed to the patient's dysfunction and pain. Therefore, the patient underwent resurfacing of the proximal humerus and biceps tenodesis. Full-thickness chondral defects were observed before resurfacing (Figure 3B). Bone grafting of the greater tuberosity was not undertaken because the defect would probably resolve with time following the initial debridement.

Postoperatively, the patient completed additional physical therapy and was weaned off all narcotics and NSAIDs. At most recent follow-up >3 years postoperatively, the patient had pain-free ROM of the left shoulder and excellent alignment (Figure 4), and had returned to all activities.

## DISCUSSION

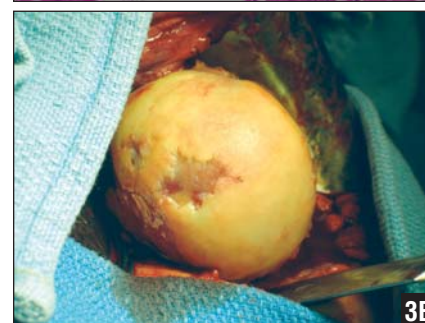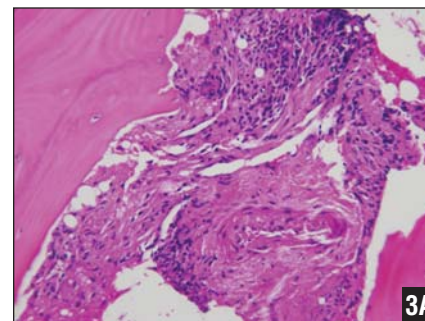
Illness from the influenza virus commonly results in self-limited myalgias, fevers, and respiratory problems, but more serious cases have resulted in >200,000 hospitalizations and 36,000 deaths each year in the United States.<sup>3</sup> Young and elderly individuals and those with comorbid conditions that may result in an immunocompromised state are at the highest



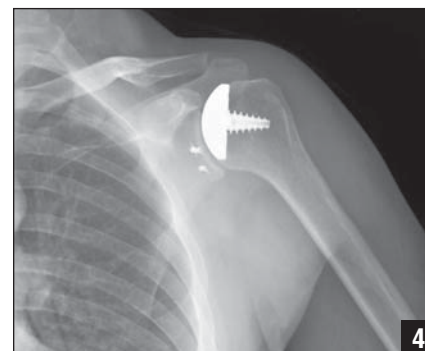
**Figure 2:** Coronal T2-weighted magnetic resonance imaging of the left shoulder showing progression in the size of the area of abnormal signal enhancement laterally in the greater tuberosity of the humeral head compared with the initial shoulder magnetic resonance imaging.

risk for developing serious complications from influenza infection.<sup>3</sup> Therefore, thousands of individuals receive an annual influenza vaccination as an important preventative medical intervention, including >50% of individuals older than 65 years.<sup>2</sup> Complications following influenza vaccination are infrequent and tend to be mild and self-limiting. The actual frequency of postvaccination side effects is not known, but they include low-grade fever, localized discomfort, swelling, and erythema.<sup>1</sup>

To the best of our knowledge, we present the first reported case of progressive osteolysis and reactive chondrolysis following influenza immunization. Intra-articular and intraosseous vaccination placement is thought to be the reason for the observed findings. Currently, no medical or surgical interventions are described for this problem. In our case, an operative approach was undertaken after all conservative measures were exhausted. The area of lateral humeral head osteolysis was treated with thorough debridement and irrigation. The extensive humeral head chondrolysis and biceps tendonitis were addressed with prosthetic humeral head resurfacing and biceps tenodesis. Postoperative rehabilitation with physical



**Figure 3:** Photomicrograph of a tissue specimen from the greater tuberosity cystic lesion showing focal intertrabecular fibrosis with mild, chronic inflammation (hematoxylin-eosin stain,  $\times 200$ ) (A). Intraoperative view of the humeral head following surgical exposure through an anterior approach using the deltopectoral interval. Photograph of a gross specimen showing generalized cartilaginous surface damage with multiple areas of full-thickness defects (B).



**Figure 4:** Postoperative anteroposterior radiograph of the left shoulder showing humeral head arthroplasty. The osteolytic area involving the greater tuberosity of the humeral head resolves as the area fills in with bone.

therapy guidance was essential to complete resolution of all symptoms.

When progressive proximal humerus osteolysis is demonstrated on serial radiographs, the differential diagnosis may include but is not limited to several genetically based or idiopathic diseases second-

ary to inoculation of a foreign substance. Genetic and idiopathic syndromes may include Farber's disease, idiopathic multicentric osteolysis (carpal-tarsal osteolysis), Winchester's syndrome, and neurogenic osteolysis.<sup>4,5</sup> In addition, Gorham's disease must be considered in the differential when osteolytic changes are present in the proximal humerus. Proliferation of vascular fibrous tissue with resultant bone resorption characterizes this rare disease and may cause massive osteolysis.<sup>4</sup> A thorough patient history, observation period, and sequential imaging help to exclude Gorham's disease, whose treatment may include bisphosphonates, radiation therapy, interferons, and surgical intervention.<sup>4</sup> Our patient had no underlying genetic disorder, and his shoulder dysfunction and radiographic evidence of osteolysis coincided with the influenza immunization.

Chondrolysis of the glenohumeral joint is a condition in which chondrocyte death follows exposure to a toxic substance, which rarely occurs during arthroscopic shoulder procedures.<sup>6,7</sup> The true etiology of chondrocyte death following arthroscopy is not fully understood, but may include thermal damage, prominent implants, or intra-articular pain pump infusions.<sup>6,8</sup> Patients with symptomatic glenohumeral chondrolysis following shoulder arthroscopy typically return to the orthopedist 6 to 24 months following the index procedure and report shoulder pain, limited ROM, and shoulder dysfunction.<sup>6,8</sup> In published series, postoperative radiographs reveal rapid, progressive loss of the glenohumeral joint.<sup>6,7</sup> In addition, MRI may reveal subchondral marrow edema and sclerosis, which typically involve the medial border of the humeral head opposing the superior glenoid.<sup>7</sup> If conserva-

tive measures fail, prosthetic or biological glenohumeral resurfacing procedures become options.<sup>6</sup> In our case, we were uncertain whether chondrolytic changes of the humeral head were present or established at the initial arthroscopy >10 years prior to influenza immunization. However, the patient's shoulder was asymptomatic and fully functional for >12 years prior to vaccination and became problematic following vaccination. The influenza immunization caused inflammatory changes in the shoulder joint as confirmed with arthroscopic visualization and histopathologic examination, which likely induced humeral head chondrolysis or converted an asymptomatic chondrolytic process to a symptomatic shoulder condition with limited ROM and function.

In patients presenting with progressive shoulder pain and dysfunction, osteonecrosis of the humeral head must be considered. This disease occurs following injury to the vasculature supplying the humeral head and may cause subchondral bone death, bone collapse, and loss of the humeral head shape with resultant abnormal glenohumeral articulation.<sup>9</sup> Our patient had no history of hemoglobinopathy, connective tissue disorder, alcohol use, corticosteroid use, recent traumatic event, or occupational hazard (Caisson disease), which can all be related to the development of humeral head osteonecrosis.<sup>9,10</sup> Furthermore, the progressive radiographic changes as described by Cruess<sup>11</sup> were not observed in our patient. Magnetic resonance imaging revealed no subchondral hyperemia, fractures, or collapse.

This case should not discourage individuals from pursuing yearly immunization because it has proven to be a successful intervention combating seasonal influenza.<sup>3</sup> However, we report humeral head

osteolysis and surface chondrolysis as a potential complication following improper immunization placement. Severe shoulder pain and dysfunction coupled with progressive osteolysis and chondrolysis may require surgical debridement and resurfacing if all conservative measures fail. ■

## REFERENCES

1. US Department of Health and Human Services. Inactivated influenza vaccine 2008-09: what you need to know. Elk Grove Village, IL: Centers for Disease Control and Prevention, US Dept of Health and Human Services; 2008.
2. Bodor M, Montalvo E. Vaccination-related shoulder dysfunction [published online ahead of print September 8, 2006]. *Vaccine*. 2007; 25(4):585-587.
3. Rothberg MB, Haessler SD, Brown RB. Complications of viral influenza. *Am J Med*. 2008; 121(4):258-264.
4. Patel DV. Gorham's disease or massive osteolysis. *Clin Med Res*. 2005; 3(2):65-74.
5. Carr JB. Osteolysis of the proximal humerus. *Orthopedics*. 2003; 26(11):1099.
6. McNickle AG, L'Heureux DR, Provencher MT, Romeo AA, Cole BJ. Postsurgical glenohumeral arthritis in young adults [published online ahead of print June 9, 2009]. *Am J Sports Med*. 2009; 37(9):1784-1791.
7. Sanders TG, Zlatkin MB, Paruchuri NB, Higgins RW. Chondrolysis of the glenohumeral joint after arthroscopy: findings on radiography and low-field-strength MRI. *AJR Am J Roentgenol*. 2007; 188(4):1094-1098.
8. Saltzman M, Mercer D, Bertelsen A, Warne W, Matsen F. Postsurgical chondrolysis of the shoulder. *Orthopedics*. 2009; 32(3):215.
9. Cushner MA, Friedman RJ. Osteonecrosis of the humeral head. *J Am Acad Orthop Surg*. 1997; 5(6):339-346.
10. Sarris I, Weiser R, Sotereanos DG. Pathogenesis and treatment of osteonecrosis of the shoulder. *Orthop Clin North Am*. 2004; 35(3):397-404.
11. Cruess RL. Experience with steroid-induced avascular necrosis of the shoulder and etiologic considerations regarding osteonecrosis of the hip. *Clin Orthop Relat Res*. 1978; (130):86-93.