

Technical Note

The Arthroscopic Latarjet Procedure for the Treatment of Anterior Shoulder Instability

Laurent Lafosse, M.D., Etienne Lejeune, M.D., Antoine Bouchard, M.D., Carlos Kakuda, M.D., Reuben Gobezie, M.D., and Tony Kochhar, M.Sc., F.R.C.S.(Tr&Orth)

Abstract: Anterior instability is a difficult clinical problem that is treated by a variety of open and arthroscopic methods with good results. Bankart repair remains a popular option. However, in those situations involving irreparable ligamentous damage or bony deficiency, this technique may be insufficient to stabilize the shoulder. One of the principal methods of open treatment for this problem is the Latarjet procedure, as described in his article in 1954. It has proven to be a durable and reliable method of treatment for anteroinferior instability of the glenohumeral joint. Several authors have reported on the long-term outcomes of this procedure with satisfactory results. There has been no previous description of the Latarjet procedure being performed arthroscopically. We present the first report of a new surgical technique, the arthroscopic Latarjet procedure. This procedure is fully arthroscopic and combines the advantages of the open procedure with those of arthroscopic stabilization. This is a significant step forward in the development of arthroscopic shoulder reconstruction and enables shoulder surgeons to treat all cases of instability arthroscopically. **Key Words:** Shoulder—Instability—Arthroscopy—Stabilization—Latarjet—Bony defect.

Arthroscopic shoulder reconstruction has become a preferred method for the treatment of shoulder instability for many surgeons. To date, arthroscopic Bankart repair has become increasingly popular, with reported outcomes that are comparable to open reconstruction, including the open Latarjet and Bankart procedures.¹⁻⁵ However, numerous studies have shown

that bony Bankart or humeral avulsion of the glenohumeral ligament (HAGL) lesions treated by Bankart repair (open or arthroscopic) may result in unsatisfactory outcomes.^{1,6} In those cases with bony defects, ligamentous insufficiency, HAGL lesion, or previous failure of Bankart repair, the Latarjet procedure, which includes the transfer of the coracoid process, has been advocated as a very popular method of treatment for anterior instability.⁷

The success of the Latarjet procedure is a result of several important factors. First, the coracoid transfer reconstructs the bony architecture of the anterior rim of the glenoid. This transfer results in an increased glenoid articular arc, thus preventing an otherwise engaging Hill-Sachs lesion from approaching the anteroinferior rim. In addition, the coracobrachialis serves as a dynamic reinforcement of the inferior part of the capsule after the transfer. The split subscapularis tendon provides dynamic stability because intersection of the transferred conjoint tendon adds dynamic tension to the inferior portion of the subscap-

From the Department of Orthopaedic Surgery (L.L., E.L., A.B., C.K., T.K.), Alps Surgery Institute, Annecy, France; and Department of Orthopaedic Surgery (R.G.), Case Western Reserve University, Cleveland, Ohio, U.S.A.

The authors report no conflict of interest.

Address correspondence and reprint requests to Laurent Lafosse, M.D., Department of Orthopaedic Surgery, Clinique Generale, 4 Ch Tour La Reine, 74000 Annecy, France.

© 2007 by the Arthroscopy Association of North America

Cite this article as: Lafosse L, Lejeune E, Bouchard A, Kakuda C, Gobezie R, Kochhar T. The arthroscopic Latarjet procedure for the treatment of anterior shoulder instability. Arthroscopy 2007; 23:1242.e1-1242.e5 [doi:10.1016/j.arthro.2007.06.008].

0749-8063/07/2311-6605\$32.00/0

doi:10.1016/j.arthro.2007.06.008

ularis as the shoulder moves into external rotation and abduction. Finally, the capsule can be reattached to the graft inferiorly, further increasing joint stability. To date, this method of stabilization has only been reported as an open procedure.

SURGICAL TECHNIQUE

Our procedure consists of 5 stages. We prepare the patient in a standard manner for shoulder arthroscopy in a beach-chair position.

First Stage: Achieving Exposure

The arthroscope is inserted through the posterior portal and the probe through the anterior portal. After assessment of the joint and surrounding structures and identification of other lesions (e.g., HAGL lesion), an anterior capsulectomy is performed with a shaver. The rotator interval is opened with partial sectioning of the anterior part of the superior glenohumeral and coracohumeral ligaments, and the articular surface of the subscapularis tendon is debrided (to facilitate the transfer of the coracoid graft). The debridement continues to allow exposure of the inferior pole of the coracoid.

The debridement consists of exposure and subsequent resection of the anterior labrum and middle glenohumeral ligament (between 2 o'clock and 5 o'clock). The surgeon must take care to retain the attachment of the superior band of the inferior glenohumeral ligament. If the inferior glenohumeral ligament is damaged, it is possible to reattach it with anchor sutures, but the transfer of the conjoint tendon may interfere with this procedure. Any other periarticular lesions (SLAP or labral tears) should be attended to at this stage.

The rotator interval is opened between the anterior border of the coracohumeral ligament and the superior part of the subscapularis tendon to grant access to the coracoid graft. The coracoacromial ligament is sectioned at its insertion to the coracoid, and the conjoint tendon is separated from the aponeurosis on the deep surface of the deltoid muscle. The anterior glenoid rim is debrided with soft-tissue shavers and a bur in preparation for the graft (2 o'clock to 6 o'clock).

Second Stage: Coracoid Preparation

In the second stage, the arthroscope is placed through the lateral portal and instrument in the anterior portal. The debridement is completed, and the coracoid area is exposed, particularly to expose the axillary nerve,

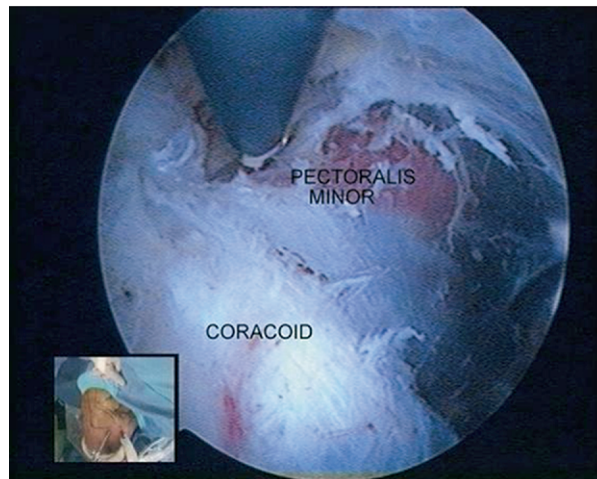


FIGURE 1. Section of tendon of pectoralis minor from coracoid process, after exposure of brachial plexus above and underneath tendon (lateral view, C portal). The inset shows the exterior view of the portals and instruments during dissection about the coracoid process.

which is located at the anterior part of the subscapularis muscle.

The lateral border of the entire conjoint tendon is debrided both laterally and medially from the pectoralis minor (Fig 1). The plexus is exposed above the tendon of the pectoralis minor. Finally, with a needle, the coracoid portal is located and opened, midway between the base and tip of the coracoid process.

Third Stage: Coracoid Drilling and Osteotomy

In the third stage, the arthroscope is placed through the anterior portal, with instrumentation used via the coracoid portal. Once the coracoid is fully exposed, the tendon of the pectoralis minor is sectioned. The entrance of the musculocutaneous nerve into the medial border of the biceps is visualized. The surgeon must take great care here because there is little distinction between the medial border of the conjoint tendon and the lateral edge of the pectoralis minor. The plexus lies just behind the pectoralis minor, so the detachment should be as close as possible to the coracoid. This allows better visualization of the brachial plexus, particularly the axillary neurovascular bundle, behind the musculocutaneous nerve.

The inferior half of the coracoid is debrided and prepared for osteotomy with a bur. By use of a 2.9-mm drill, 2 drill holes are made 8 mm apart vertically into the coracoid (Fig 2). A special guide lock is used to ensure adequate separation of the drill holes. With the aid of 2 long hooks, a length of suture (Orthocord; DePuy

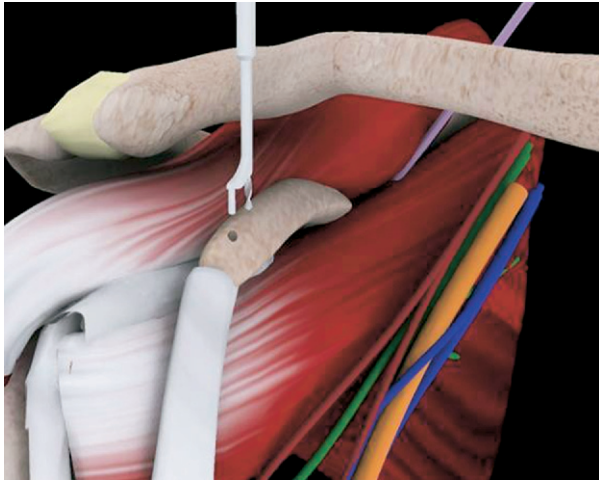


FIGURE 2. Coracoid drilling via a special guide lock to ensure adequate separation of drill holes.

Mitek, Raynham, MA) is passed through the 2 holes, forming a U shape, and is retrieved through the coracoid portal. The 2 sutures are passed through a small rigid guide tube.

A coracoid osteotomy is performed 2 to 2.5 cm above the tip of the coracoid, at the union between the horizontal and vertical part of the coracoid (with an apex at the angle previously prepared by the bur), by use of an osteotome and mallet (**Fig 3**). The coracoid is then mobilized inferiorly and medially to expose the anterior subscapularis.

Fourth Stage: Coracoid Transfer

During the fourth stage, the arthroscope is placed through the lateral portal, with instrumentation used via the anteroinferior portal. By use of a long needle and then a smooth blunt trocar, the anteroinferior portal is identified and opened, through the subscapularis tendon, lateral to the axillary nerve. This portal grants excellent access to the anterior rim of the glenoid (from 1 o'clock to 6 o'clock) and is in the exact direction of the screws for fixation of the coracoid at the anterior border of the glenoid. The subscapularis tendon is split horizontally.

With the use of an ablation diathermy probe, the debridement increases exposure laterally from the axillary nerve to the lateral insertion of the subscapularis tendon on the lesser tuberosity at the junction of the superior third and inferior two thirds (just at the level of the anterior vessels) from the axillary nerve medially to the insertion of the tendon laterally. The sur-

geon must pay close attention not to open the bicipital groove.

A smooth 2-cm trocar ensures adequate splitting of the muscle and access into the joint. A switching stick is introduced through the posterior portal parallel to the glenoid and passes through the split in the subscapularis tendon to create room for the passage of the coracoid graft (by moving the upper part of the muscle superiorly as a lever arm). Because the direction of the switching stick is exactly in line with the brachial plexus, it is essential that the surgeon pay close attention to the manipulation of the tip of the switching stick to move it laterally away from the plexus.

By use of a special cannula (through the anteroinferior portal), 2 cannulated guide screws are inserted with the aid of the sutures into the drill holes in the coracoid. This device locks the coracoid process and allows complete control during graft positioning. The graft is then mobilized through the split subscapularis tendon (helped by the switching stick) and positioned on the anterior rim of the glenoid.

Fifth Stage: Fixation of Bone Graft

For the final stage, the arthroscope is placed through the anterior portal, with instrumentation through the anteroinferior portal. The graft is accurately positioned at the anterior border of the glenoid (from 2 o'clock to 6 o'clock, at the level of the glenoid surface), which is confirmed by the arthroscope, which passes from inside to outside the joint, above the subscapularis tendon. A guidewire is drilled through

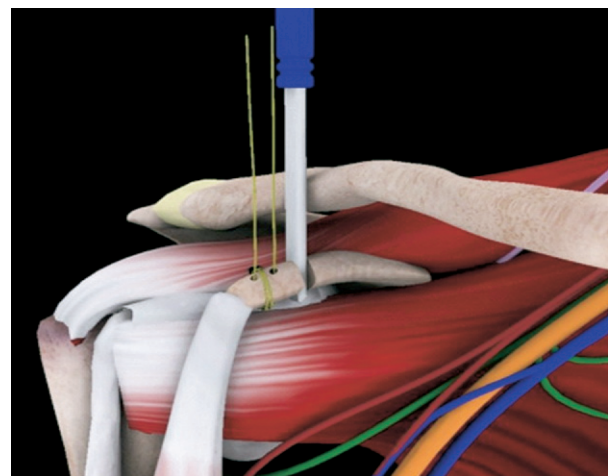


FIGURE 3. The osteotome has divided the coracoid process. Two sutures act as a "cable car" to allow manipulation and transposition of the glenoid graft.

one of the guide screws, either superiorly or inferiorly, into the glenoid for temporary fixation. It is very important to apply one screw completely before placement of the second K-wire and screw because attempts to apply both K-wires and screws simultaneously will result in distraction of the coracoid bone block from the anterior-inferior glenoid and scapular neck.

The first wire is pushed through the posterior cortex of the glenoid and allowed to perforate the skin posteriorly under the spine of the scapula. The sharp tip of the guidewire is clamped posteriorly to prevent it from pulling back into the wound. Because the direction of the guidewire is oblique and medial to the glenoid neck, it is not in the way of the suprascapular nerve. The wires exit approximately 4 to 5 cm directly medial to the posterior portal.

The guide screw is removed, and a 3.5-mm cannulated drill bit is used to drill over the wire. Next, the screw is measured, and once the screw is approximately 5 mm inside the glenoid, the guidewire is removed posteriorly. The coracoid bone block is reduced to the glenoid and scapular neck under direct visualization via the arthroscope.

The screw is pushed until the head appears close to the anterior cortex of the coracoid but is not tightened completely until the second screw is introduced. The second screw is inserted in the same way as previously described for the first screw, and final compression of both screws is performed under arthroscopic visualization (Fig 4).

The positioning of the bone graft is controlled through the anterior and posterior portals. In case of

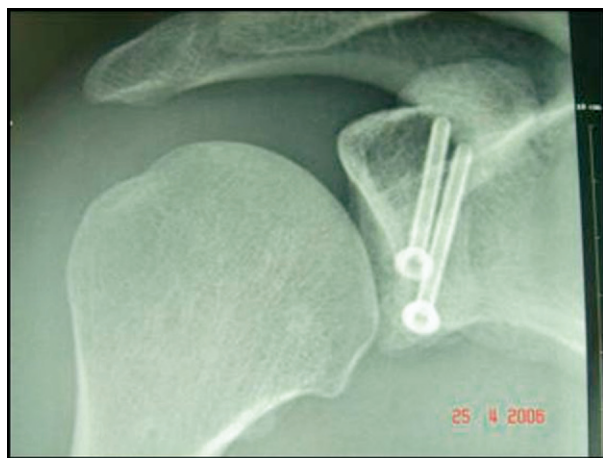

FIGURE 4. Final radiograph showing screw placement after arthroscopic Latarjet procedure.

an anterior step at the glenoid-graft interface, a bur can be used to obtain a flat graft, parallel to the glenoid surface.

DISCUSSION

The technique for the transfer of the coracoid process and its attached conjoined tendon to the anterior glenoid and fixation with screws was first described by Latarjet⁸ in 1954. In the original article the superior third of the subscapularis tendon was detached to pass the graft with the conjoined tendon over the inferior part. In the English-language literature this procedure became popularized after the publication by Helfet⁹ of a modification of the technique shown to him by Dr. W. Rowley Bristow.

The Latarjet procedure is a reliable method of treatment for anterior instability, with good results reported in many studies.¹⁰⁻¹⁶ The functional results and outcome after a Latarjet procedure seem to be similar to those seen after a Bankart procedure, with many comparative studies reporting no difference in outcome score or recurrence.^{4,5,10,17}

Surgeons and patients believe that arthroscopic shoulder reconstruction may result in reduced scarring and tissue damage, excellent exposure, reduced risk of infection, and faster rehabilitation.^{2,5,16,18-24} The risks associated with open reconstruction (late chondrolysis, implant loosening or failure) are also thought to be reduced.^{5,25-28}

This procedure is generally indicated at either of two stages: after preoperative assessment (particularly in cases of bony insufficiency or recurrence or in athletes participating in contact sports)⁶ or after arthroscopic assessment of the shoulder joint and the periarticular structures (e.g., clinical examination may be equivocal but the arthroscopy may reveal an irreparable ligament lesion or an HAGL lesion).⁷

The ability of a surgeon to visualize the shoulder from different angles, via various portals, only serves to improve the exposure. In comparison, the open procedure can often be complicated by a limited exposure, especially in young athletes with significant musculature. The arthroscopic technique is certainly advantageous in those cases in which the preoperative assessment fails to reveal an HAGL lesion or a large bony avulsion from the anterior rim, and it allows a surgeon to modify his or her plan intraoperatively.

With regard to graft placement and fixation, the arthroscopic technique provides superior visualization for positioning the coracoid, which should minimize the risk of anterior overhang of the bone block and

thereby reduce the risk of rapid-onset osteoarthritis of the humeral head (a recognized complication of open procedures).

The technique described is a complex procedure and requires a degree of experience and expertise. It is a reproducible technique, and in our experience the learning curve shows a reduction of the surgical time from 4 hours for the first procedure to 1 hour 15 minutes for most recent cases. It is an excellent option for revision cases.

The senior author has performed 44 cases in the last 2 years, without complication from neurovascular injury or infection. Preliminary reports indicate excellent clinical results.

This technique offers the option of an arthroscopic method of treatment for patients with shoulder instability. It is a complementary arthroscopic treatment to the soft-tissue repair, which enables the arthroscopic management of all scenarios of instability.

REFERENCES

- Walch G, Boileau P, Levigne C, Mandrino A, Neyret P, Donell S. Arthroscopic stabilization for recurrent anterior shoulder dislocation: Results of 59 cases. *Arthroscopy* 1995;11:173-179.
- Kim SH, Ha KI, Cho YB, Ryu BD, Oh I. Arthroscopic anterior stabilization of the shoulder: Two to six-year follow-up. *J Bone Joint Surg Am* 2003;85:1511-1518.
- Westerheide KJ, Dopirak RM, Snyder SJ. Arthroscopic anterior stabilization and posterior capsular plication for anterior glenohumeral instability: A report of 71 cases. *Arthroscopy* 2006;22:539-547.
- Mohtadi NG, Bitar IJ, Sasyniuk TM, Hollinshead RM, Harper WP. Arthroscopic versus open repair for traumatic anterior shoulder instability: A meta-analysis. *Arthroscopy* 2005;21:652-658.
- Cole BJ, Warner JJ. Arthroscopic versus open Bankart repair for traumatic anterior shoulder instability. *Clin Sports Med* 2000;19:19-48.
- Burkhart SS, De Beer JF. Traumatic glenohumeral bone defects and their relationship to failure of arthroscopic Bankart repairs: Significance of the inverted-pear glenoid and the humeral engaging Hill-Sachs lesion. *Arthroscopy* 2000;16:677-694.
- Boileau P, Villalba M, Hery JY, Balg F, Ahrens P, Neyton L. Risk factors for recurrence of shoulder instability after arthroscopic Bankart repair. *J Bone Joint Surg Am* 2006;88:1755-1763.
- Latarjet M. Treatment of recurrent dislocation of the shoulder. *Lyon Chir* 1954;49:994-997 (in French).
- Helfet AJ. Coracoid transplantation for recurring dislocation of the shoulder. *J Bone Joint Surg Br* 1958;40:198-202.
- Hovelius LK, Sandstrom BC, Rosmark DL, Saebo M, Sundgren KH, Malmqvist BG. Long-term results with the Bankart and Bristow-Latarjet procedures: Recurrent shoulder instability and arthropathy. *J Shoulder Elbow Surg* 2001;10:445-452.
- Chen AL, Hunt SA, Hawkins RJ, Zuckerman JD. Management of bone loss associated with recurrent anterior glenohumeral instability. *Am J Sports Med* 2005;33:912-925.
- Salvi AE, Paladini P, Campi F, Porcellini G. The Bristow-Latarjet method in the treatment of shoulder instability that cannot be resolved by arthroscopy. A review of the literature and technical-surgical aspects. *Chir Organi Mov* 2005;90:353-364.
- Hovelius L, Sandstrom B, Sundgren K, Saebo M. One hundred eighteen Bristow-Latarjet repairs for recurrent anterior dislocation of the shoulder prospectively followed for fifteen years: Study I—Clinical results. *J Shoulder Elbow Surg* 2004;13:509-516.
- Russo R, Togo F, Jannelli E. The surgical treatment of recurrent anterior dislocation of the shoulder. *Ital J Orthop Traumatol* 1990;16:183-189.
- Yoneda M, Hayashida K, Wakitani S, Nakagawa S, Fukushima S. Bankart procedure augmented by coracoid transfer for contact athletes with traumatic anterior shoulder instability. *Am J Sports Med* 1999;27:21-26.
- Nourissat G, Nedellec G, O'Sullivan NA, et al. Mini-open arthroscopically assisted Bristow-Latarjet procedure for the treatment of patients with anterior shoulder instability: A cadaver study. *Arthroscopy* 2006;22:1113-1138.
- Tjoumakaris FP, Abboud JA, Hasan SA, Ramsey ML, Williams GR. Arthroscopic and open Bankart repairs provide similar outcomes. *Clin Orthop Relat Res* 2006;227-232.
- Guanche CA, Quick DC, Sodergren KM, Buss DD. Arthroscopic versus open reconstruction of the shoulder in patients with isolated Bankart lesions. *Am J Sports Med* 1996;24:144-148.
- Millett PJ, Clavert P, Warner JJ. Open operative treatment for anterior shoulder instability: When and why? *J Bone Joint Surg Am* 2005;87:419-432.
- Geiger DF, Hurley JA, Tovey JA, Rao JP. Results of arthroscopic versus open Bankart suture repair. *Clin Orthop Relat Res* 1997:111-117.
- Grana WA, Buckley PD, Yates CK. Arthroscopic Bankart suture repair. *Am J Sports Med* 1993;21:348-353.
- Mologne TS, Lapoint JM, Morin WD, Zilberfarb J, O'Brien TJ. Arthroscopic anterior labral reconstruction using a transglenoid suture technique. Results in active-duty military patients. *Am J Sports Med* 1996;24:268-274.
- Green MR, Christensen KP. Arthroscopic versus open Bankart procedures: A comparison of early morbidity and complications. *Arthroscopy* 1993;9:371-374.
- Cho NS, Hwang JC, Rhee YG. Arthroscopic stabilization in anterior shoulder instability: Collision athletes versus noncollision athletes. *Arthroscopy* 2006;22:947-53.
- Gill TJ, Micheli LJ, Gebhard F, Binder C. Bankart repair for anterior instability of the shoulder. Long-term outcome. *J Bone Joint Surg Am* 1997;79:850-857.
- Rowe CR, Patel D, Southmayd WW. The Bankart procedure: A long-term end-result study. *J Bone Joint Surg Am* 1978;60:1-16.
- Fabbricani C, Milano G, Demontis A, Fadda S, Ziranu F, Mulas PD. Arthroscopic versus open treatment of Bankart lesion of the shoulder: A prospective randomized study. *Arthroscopy* 2004;20:456-462.
- Wirth MA, Blatter G, Rockwood CA Jr. The capsular imbrication procedure for recurrent anterior instability of the shoulder. *J Bone Joint Surg Am* 1996;78:246-259.